Romanian Society of Clinical Sexology and Human Procreation

ISSN 2602-0173,
SSN-L 2602-0173
ISSN ONLINE 2668-0394

Journal of Clinical Sexology

Vol.2, No.1: January-March 2019

PUDENCY AND THE PREFRONTAL CEREBRAL CORTEX

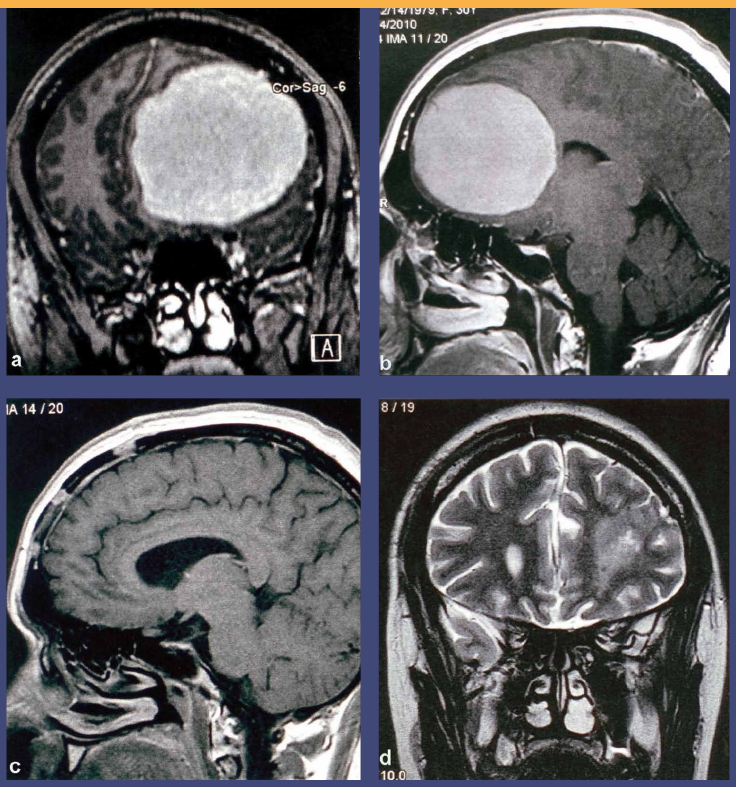

Founder and Editor-in-chief: Vasile NIȚESCU

Journal of Clinical Sexology

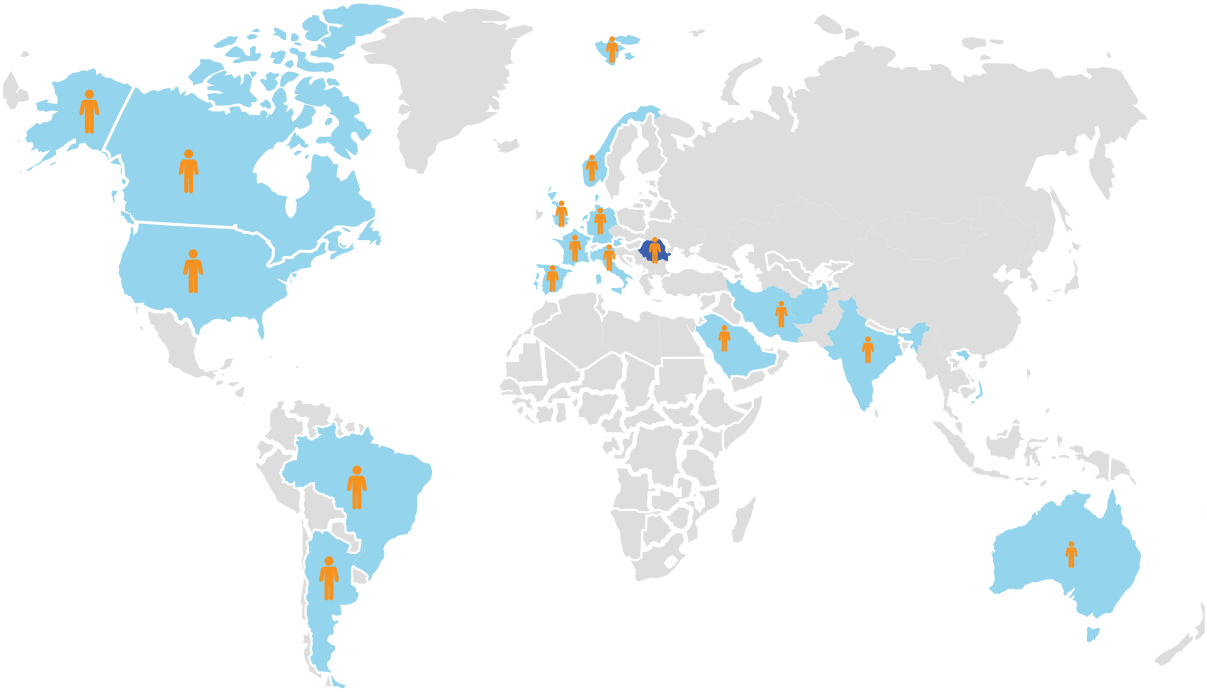

Figure 1 - Number of visitors in percent of the site www.journalofclinicalsexology.com, according to Google Analytics

RO	34%	BRAZIL	10%	ARGENTINE	0.25%
US	26%	ITALY	0.75%	INDIA	0.10%
UK	15%	AUSTRIA:	0.50%	FRANCE, SPAIN,	
AUSTRALIA	13%	GERMANY	0.35%	AFGHANISTAN	> 0.05%

JOURNAL OF CLINICAL SEXOLOGY is the official, international journal of the Romanian Society of Clinical Sexology and Human Procreation.

This is the first journal of sexology in Romania, founded in 2018. The Journal of Clinical Sexology appears four times a year and publishes original papers related to general and clinical sexology, case reports, notes, comments and actualities in medicine.

The Journal of Clinical Sexology is currently indexed in EBSCO and SCIPIO.

Contents

Editorial

Romanian Society of Clinical Sexology and Human Procreation

To the Medical Academy of the State of Mineira, Brazil

Mr. President of the Academy José Raimundo Da Silva Lippi,

I am much honored to have been chosen as an „Effective Corresponding Member" of the Academy you are leading and I would like to show my appreciation.

I thank Professor Academician Dr. Andy Petroianu, a personality of Brazilian surgery, who proposed me, as well as the members of the Academy who unanimously voted for me.

I am particularly impressed and grateful for the honourable words and eulogistic appreciation of the „Treaty of Clinical Sexology" and the magazine „Journal of Clinical Sexology".

I hope they would benefit to the members of the Academy and Library in Brazil.

Thank you for your honorable words,
President, Associate Professor Dr. Nitescu Vasile

The undersigned, President of the Romanian Society of Clinical Sexology and Human Procreation - Associate Professor Dr. Nițescu Vasile

I am honored to inform you that I was awarded the title of "Corresponding Member" of the Medical Academy in Mineira-Brazil.

The President of the Academy José Raimundo Da Silva Lippi and the Academician Dr. Andy Petroianu appreciated in praised terms the works published in the magazine "Journal of Clinical Sexology", and the other papers and books that I have edited, considering them scientifically valuable, which is why I have sincerely thanked them.

Original article

Received: 18 .01.2019
Accepted: 1.02.2019

PUDENCY AND THE PREFRONTAL CEREBRAL CORTEX

[1] Leon DĂNĂILĂ, [2] Vasile NIȚESCU
[1] National Institute of Neurology and Neurovascular Diseases
[2] Medical Centre of Obstetrics-Gynecology and Sexology

Abstract:

The disorders of sexual behaviour constituting the pudency are determined by the prefrontal cortex, subdivision of the cerebral cortex. The connection with other cortical, subcortical and autonomic nervous areas determines the ability to control emotions, behaviors, and inhibits inadequate responses. The surgical treatment of the lesions directly interested in the prefrontal cortex removed the symptoms specific to the pudency.

Keywords:

pudency, prefrontal cortex, cognitive part , behavioural disorders

Correspondence to: [1]Leon Dănăilă Acad., MD., PhD, 10-12 Berceni Street, post code 41914, 4 District, Bucharest, Romania,Fax: (021) 334.64.63,E-mail: manager_ibcv@yahoo.com

[2]Nițescu Vasile MD., Ph.D, 9 Washington Street, 1st District, post code 011792, Bucharest, Romania, E-mail: jcs.editorial.board@gmail.com

Introduction

Pudency is a feeling of self-consciousness, decency, reservedness, discretion, shyness and bashfulness linked to the issues of voluptuousness, of the bodily and spiritual pleasures and delights.

It involves the observance of the good manners, of the decorum and of the common sense, thus preventing the individuals to do or to say anything indecent in connection with the sexual issues. In the general way of things, pudency is reflected, or is manifested through actions, attitudes, behaviours, approaches, body postures and manners of dressing which are adequately put forth with bashfulness, shyness and noble-mindedness in order to eliminate the tendency to attract and gain the adherence of the persons of the opposite sex to the lascivious, impudent, sensual and obscene acts of voluptuousness. The extravagant luxury, the enchanting gesticulation and the manner of dressing which have the single objective to attract the persons of the opposite sex with the purpose to achieve an extremely intense fulfilment of the bodily instincts and lust, or in order to gain certain material benefits, are already considered to be within the purview of the deliberate or pathological abnormal behaviours or as an indication of the lack of self-control.

But the self-control can be influenced by a multitude of profoundly immoral commercial messages and advertisements.

This pornographic intoxication of the noetic feelings which is addressed to the spirit is much more difficult to weed out than the toxicity itself.

In order to perform the washing out of this informational abjectness we don't have at our disposal and it is not available any medicine which might heal this ghoulish wound of the mind or which can help direct us towards the behaviours which are more adequate for the normal life situations.

In many instances, mainly in the cases in which there are injuries of the prefrontal lobe, they rouse up, especially in the young individuals, whiplashes of the immoral desires which lay siege to their attention, willpower, and even life itself.

When the power of the mind moves against the nature, when reason goes out the window, it becomes preoccupied especially by pleasures.

We live today in a world of pleasure, which intensifies the desire to reduce the distances between the appetite for pleasure and its fulfilment.

In contrast to this, there are numerous passages of the philocalic writings which talk us round with regard to the importance of a close supervision of our thoughts, words and actions, as well of our life in its entirety.

Normally, the mind functions without wanderings and with no passionate perspectives, with cleanliness and pudency with regard to the reality and the rationality of the various processes, these being relatively consistent modalities for the referencing of the individual in relation to certain aspects of the social life, as well as to his own person.

It is natural that the individuals should not follow up only the living up of the voluptuousness through extremely intense feelings, appetites or sprees, that is of the indwelling and bodily pleasures which are induced by the sexual intercourse.

Methods

After more than half a century of continuous and intense activity in the field of neurosurgery, I had observed that the sense of pudency was dependant on the activity of the prefrontal cortex.

The prefrontal cortex is the most forward part of the frontal lobe of the cerebral cortex (Dănăilă and Golu, 1988; 2018).

The prefrontal cortex is a major subdivision of the cerebral cortex, which plays a critical role in the initiation of activities, in the detection and in the resolving of the conflicting plans for action, as well as in the mediation of complex processes such as attention, planning, decision making, emotion, and personality, and it is responsible for the evaluation of our actions as being either a success or a failure relative to our intention (Dănăilă, 2016; Dănăilă, 2018).

Nevertheless, the prefrontal cortex is the most distinctively cognitive and behavioural part of the brain.

As the seat of goals, foresight, and planning, the frontal lobes are perhaps the most uniquely human of all the components of the human brain.

Thus, prefrontal cortex plays the central role in the initiation of activities, in establishing the goals and objectives and then in the devising of the plans of action which are required in order to reach these goals (Dănăilă, 2016).

The physiology of a cortical region can be studied and comprehended only in the context of its anatomical connections with the other structures.

The functions of the prefrontal cortex, which are to some extent still unclear, are reciprocally supporting and complete each other during the implementation of an individual action.

The prefrontal cortex would not represent anything if it would not work in conjunction with other cortical areas, with the subcortical structures, as well as with certain areas of the motor and sensorial structures and with those of the autonomous nervous system.

As a whole, the prefrontal cortex contributes to: the achievement of the emotional functions, the sequential control of the behaviours which are necessary for the planning and the settlement of problem-solving, of the abilities and of the success in the real life, the inhibition of the inadequate responses, the automation of various actions, the ecphoration of the adequate decisional and creative capabilities and the successful projection in the past, as well as in the future.

The planning and the decision making are the two major functions of the prefrontal cortex (Dănăilă and Pascu, 2013).

During the progress of the sequences which are directed towards the achievement of a certain purpose, the signals from the internal and the external environment are processed hierarchically, whereupon the internal signals are sent towards to the orbital prefrontal cortex while the external signals are directed towards the lateral prefrontal cortex.

There, the signals which had been mentioned above will mould or will generate other actions which will enter in the processing cycle of the internal or external environment which they will change until the achievement of the intended purpose.

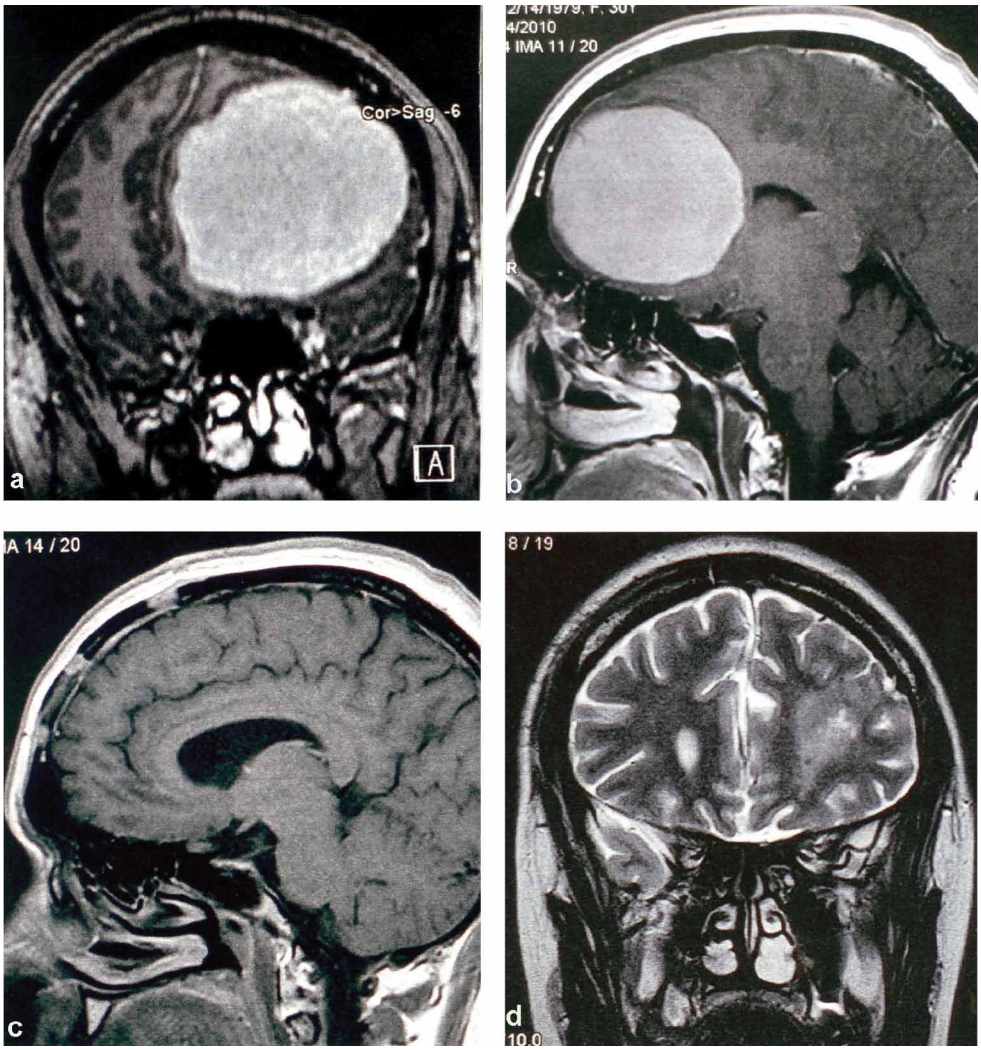

Figure 1

A 30-year-old woman who, besides the disorders which are specific to the dorsolateral prefrontal cortex, had also presented the degradation of the sense of pudency. The magnetic resonance imaging (MRI) examination had revealed on the anteroposterior and on the lateral images a large left prefrontal convexal meningioma (Figures 1a and 1b) which had been surgically resected in its entirety (Figures 1c and 1d) (surgeon Leon Dănăilă). The entire symptomatology had disappeared after the surgical treatment.

At each hierarchic level of the cycle there are generated feedback connections with the previous levels.

Without this structuring it will not be possible the occurrence of any new executive acts, either acquired or behaviourally wrought, of any fluent speech acts, of any superior rational processes, as well as of any creative activities (Dănăilă, 2018). The prefrontal cortex is located on the lateral orbital medial surface of the most anterior portion of the frontal lobe. The prefrontal cortex is the non-motor part of the frontal cortex (Dănăilă, 2018).

In humans, there is no primary sulcus which demarcates the posterior limit of the prefrontal cortex.

In the following section we shall present the three prefrontal lobe syndromes: (1) the dorsolateral prefrontal syndrome; (2) the orbitofrontal syndrome; and (3) the medial prefrontal syndrome, as well as the symptomatology in whose context into which fits the degradation of the sense of pudency.

1) The dorsolateral prefrontal syndrome

The injury of the lateral areas of the prefrontal lobes is manifested through an acquired sociopathy which comprises the following symptoms: the degradation of the sense of pudency (**Fig. 1**), the inability to inhibit the inadequate responses, the disinhibition of the instinctive behaviours, the absence of the critical sense, the disappearance of pudency, the inableness to achieve self-monitoring, the distancing of the individual from the environment, the absence of the mental flexibility and of creativity, the lack of the ability to make decisions and to plan the required actions, the inability to control the behavioural sequences, the anchorage of the individual in the present, the incapacity of the individuals to project themselves accurately and successfully both in the past and in the future, the abolishment of the degree of appropriateness of the behaviour and of the capability to anticipate the outcomes of the individual actions, as well as defects in the control, the regulation, and the integration of the cognitive activities (**Fig. 2**). The defects in the control, the regulation, and the integration of the cognitive activities tend to predominate in the patients with dorsolateral lesions, i.e., when the lesion is located on the top or on the outer side -the convexity- of the prefrontal lobes. This syndrome had been described as being a metacognitive disorganization which reflects a reduced state of mental control.

The persons concerned perform very well at tests, but they demonstrate an unintelligent performance in the everyday life.

The appearance of copulation (penetration) and ejaculatory dysfunction in mature rats, respectively the modification of sexual behaviuor in prefrontal cerebral cortex lesions were released by Agmo & Villaponda (1995) and Yamanouchi & Arai (1992).

According to some authors (Crowe & Ponsford-1999) male prefrontal cortex would play a role in determining erotic images and, in the case of those with brain trauma , they would have a lack of sexual image.

The appearance of copulation (penetration) and ejaculatory dysfunction in mature rats, respectively the modification of sexual behaviuor in prefrontal cerebral cortex lesions were released by Agmo & Villaponda (1995) and Yamanouchi & Arai (1992).

According to some authors (Crowe & Ponsford-1999) male prefrontal cortex would

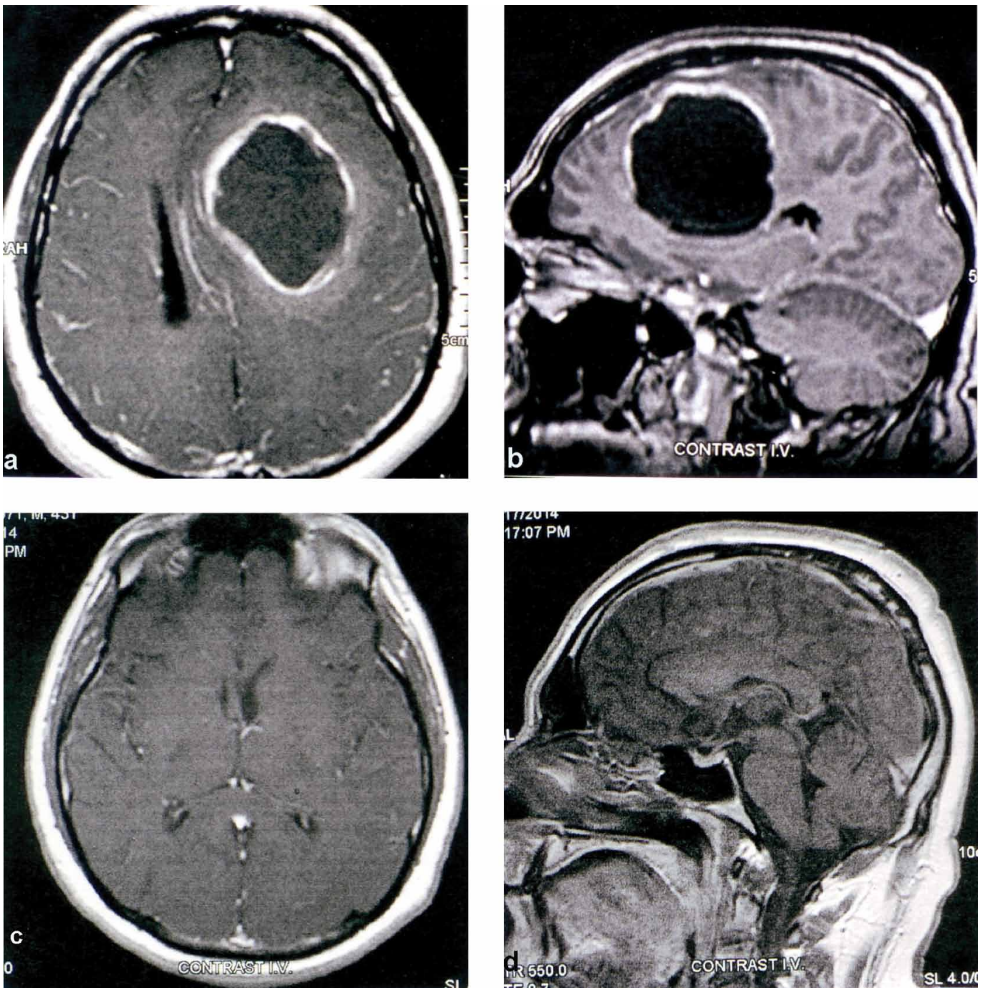

Figure 2

A 43-year-old woman who had presented with a 2-month history of moderate weakness on the right side, headache, the degradation of the sense of pudency and other disorders specific to lesions of the dorsolateral prefrontal cortex which had been described in the text.
The preoperative computed tomography (CT) scan shows the presence of a well-circumscribed left side frontal cystic astrocytoma (a and b). The postoperative CT scan demonstrates the complete removal of the tumour (c and d) (surgeon Leon Dănăilă). After four months the frontal syndrome had disappeared.

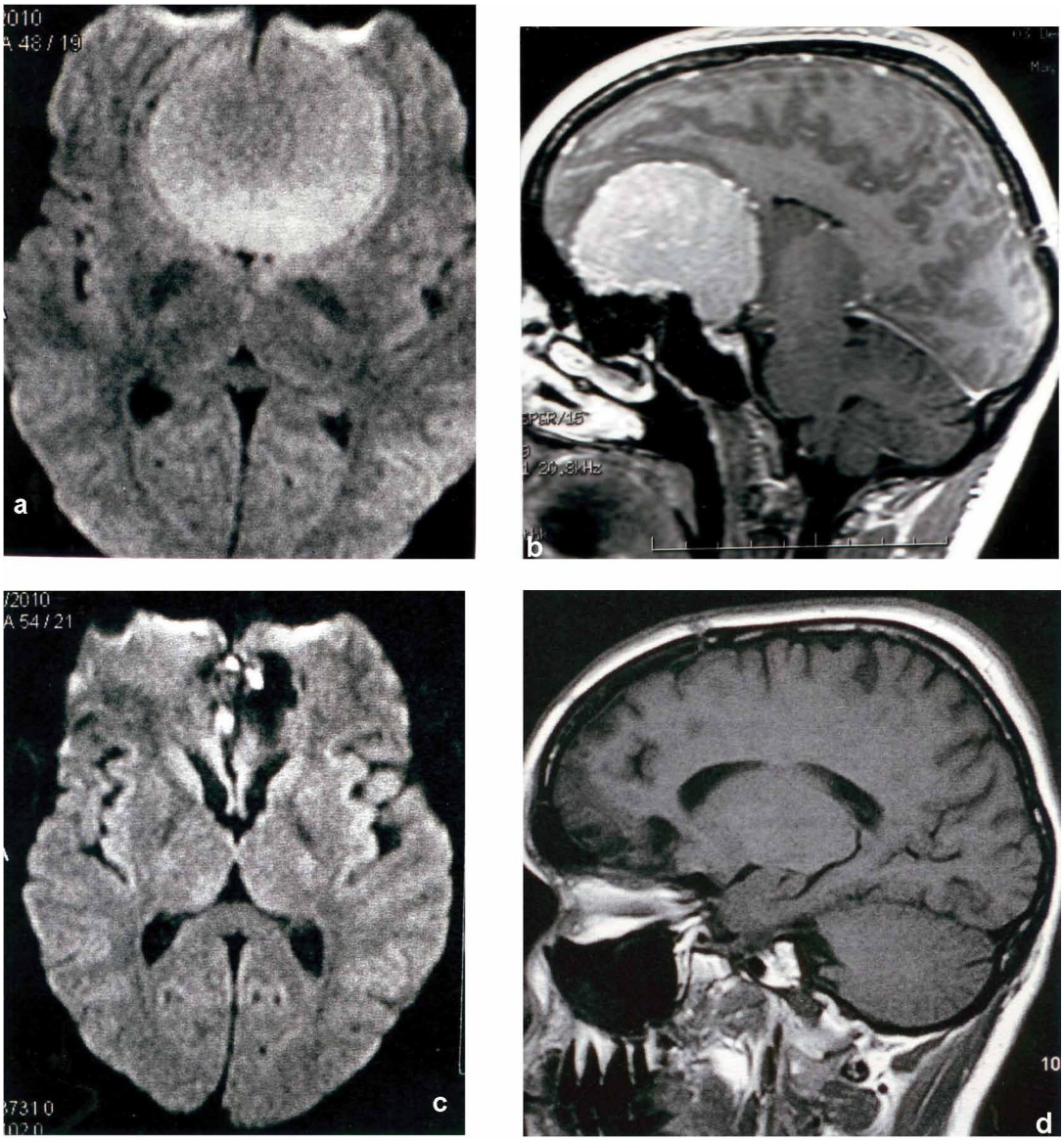

Figure 3

An olfactory groove meningioma in a 37-year-old woman who had received treatment for the degradation of the sense of pudency and for other psychiatric problems.
The CT scan images with contrast enhancement had shown the enhancing lesion located on the midline of the anterior part of the floor of the frontal fossa (a big olfactory groove meningioma) (a and b). The axial and the lateral images of the postoperative contrast-enhanced CT scan reveal the complete resection of the tumour (c and d). The frontal syndrome had disappeared after surgery (surgeon Leon Dănăilă).

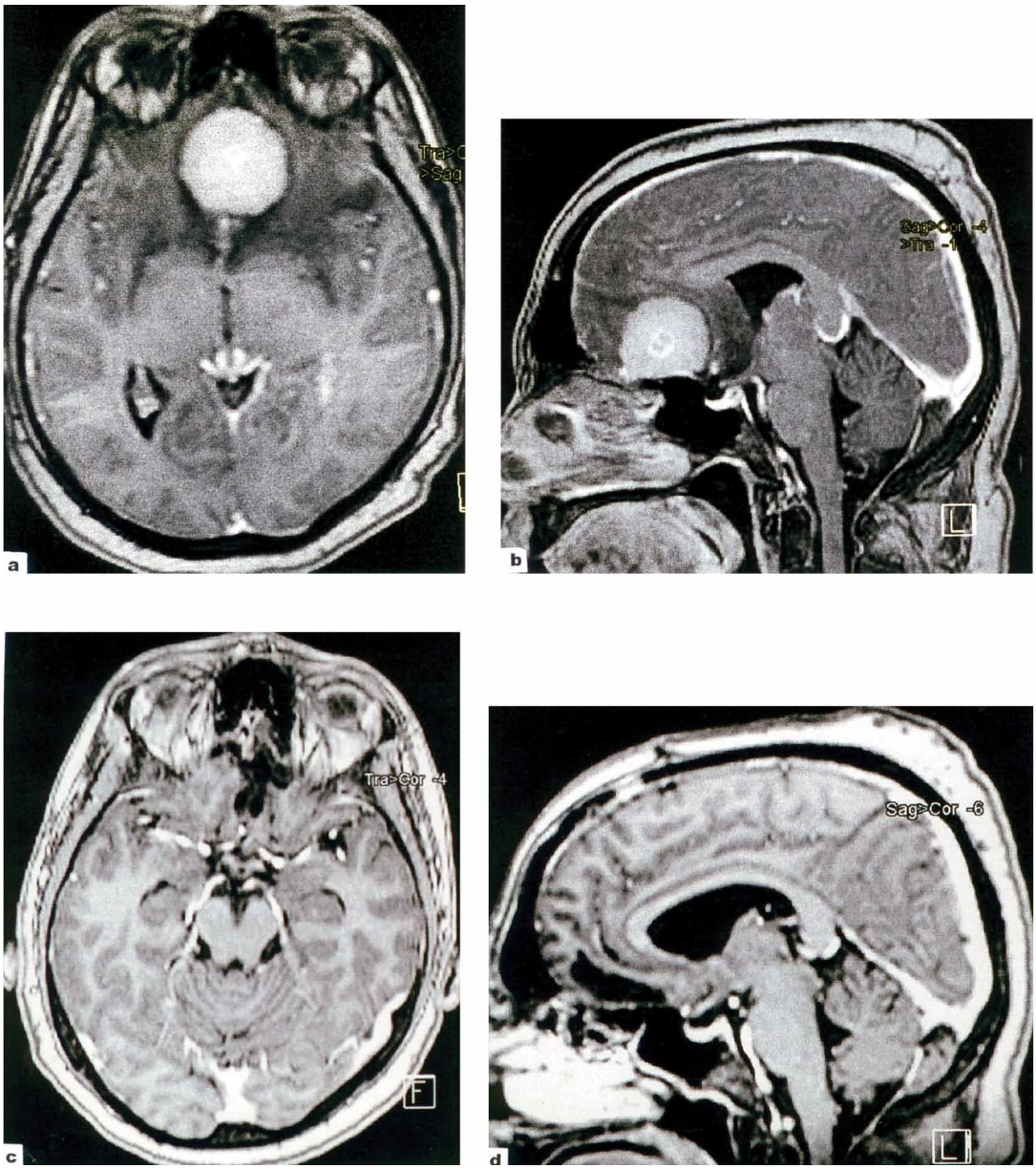

Figure 4

An olfactory groove meningioma in a 49-year-old woman who, besides several moderate characteristic disorders caused by the compression of the orbital prefrontal cortex, had also presented the degradation of the sense of pudency. The magnetic resonance imaging (MRI) examination reveals an olfactory groove meningioma with bilateral extension (a and b), which had been surgically resected in its entirety (c and d).

The symptomatology had disappeared after the surgical treatment (surgeon Leon Dănăilă).

play a role in determining erotic images and, in the case of those with brain trauma , they would have a lack of sexual image.

2) The orbitofrontal cortex lines the ventral surface of the frontal lobe on the floor of the anterior cranial fossa. The orbital (basal, ventral) prefrontal cortex plays a key role in impulse control and in the regulation and the maintenance of the on-going behaviour. In the healthy persons, this region is involved in the expression of the aggressive behaviour, but the intellect is not grossly impaired.

The damage located here can give rise to disinhibition and impulsivity, with associated behavioural problems such as aggressive outburst, misplaced jokes or withering scorns, beatitude, silliness, puerility, euphoria, disinterest, stereotypies, perseverations, the degradation of the self-criticism, of the a moral sense, the lack of the sense of pudency and sexual promiscuity (**Figures 3 and 4**).

The lesions located in the orbital frontal cortex can also disrupt a patient`s ability to be guided by the future consequences of his or her actions, thus leading to poor decision-making (Bechara et al., 1999; Dănăilă, 2018). However, they have no foresight of the consequences of their actions.

Thus, there are marked abnormalities in the realms of reasoning, personal and social decision-making, emotional control, and feelings.

The disruption in the ability to control the feelings and the emotions often results in explosive aggressive outbursts which are characterized by socially unacceptable, tactless, as well as vulgar manifestations (Dănăilă, 2018).

The most common causes of the orbitofrontal syndrome include ventral frontal meningiomas, arteriovenous malformations (**Figures 5 and 6**), injuries following the acceleration-deceleration head trauma, viral infections (e.g., the Herpes simplex encephalitis and the Creutzfeldt-Jacobs disease), as well a multiple sclerosis (Dănăilă et al., 1996; Dănăilă, 2018).

The patients with the orbitofrontal syndrome (due to cerebral tumours, cerebrovascular illnesses, and head injuries) are known to be “selfish”, boastful, puerile, profane and sexually explicit.

These patients might engage in shoplifting, in sexually aggressive behaviours, in reckless driving, or in other actions which are commonly perceived as being antisocial.

The orbitofrontal cortex intervenes in the determination of sexual arousal (Franciss et al 1999), especially through manual maneuvers (Redout et al 2000)).

Orbitofrontal cortex lesions can induce promiscuous sexual behaviour, such as public self-masturbation or exposing genital organs (Starkstein & Robinson 1997; Malloy et al. 1993; Miller et al., 1896).

Thus, this disinhibited and euphoric syndrome which is characterized by impulsivity, social inappropriate behaviour, aggressiveness and sexual disinhibition had been attributed to the orbitofrontal regions (Dănăilă, 2018).

The orbitofrontal cortex intervenes in the determination of sexual arousal (Franciss et al 1999), especially through manual maneuvers (Redoute et al 2000)).

Orbitofrontal cortex lesions can induce promiscuous sexual behaviour, such as pu-

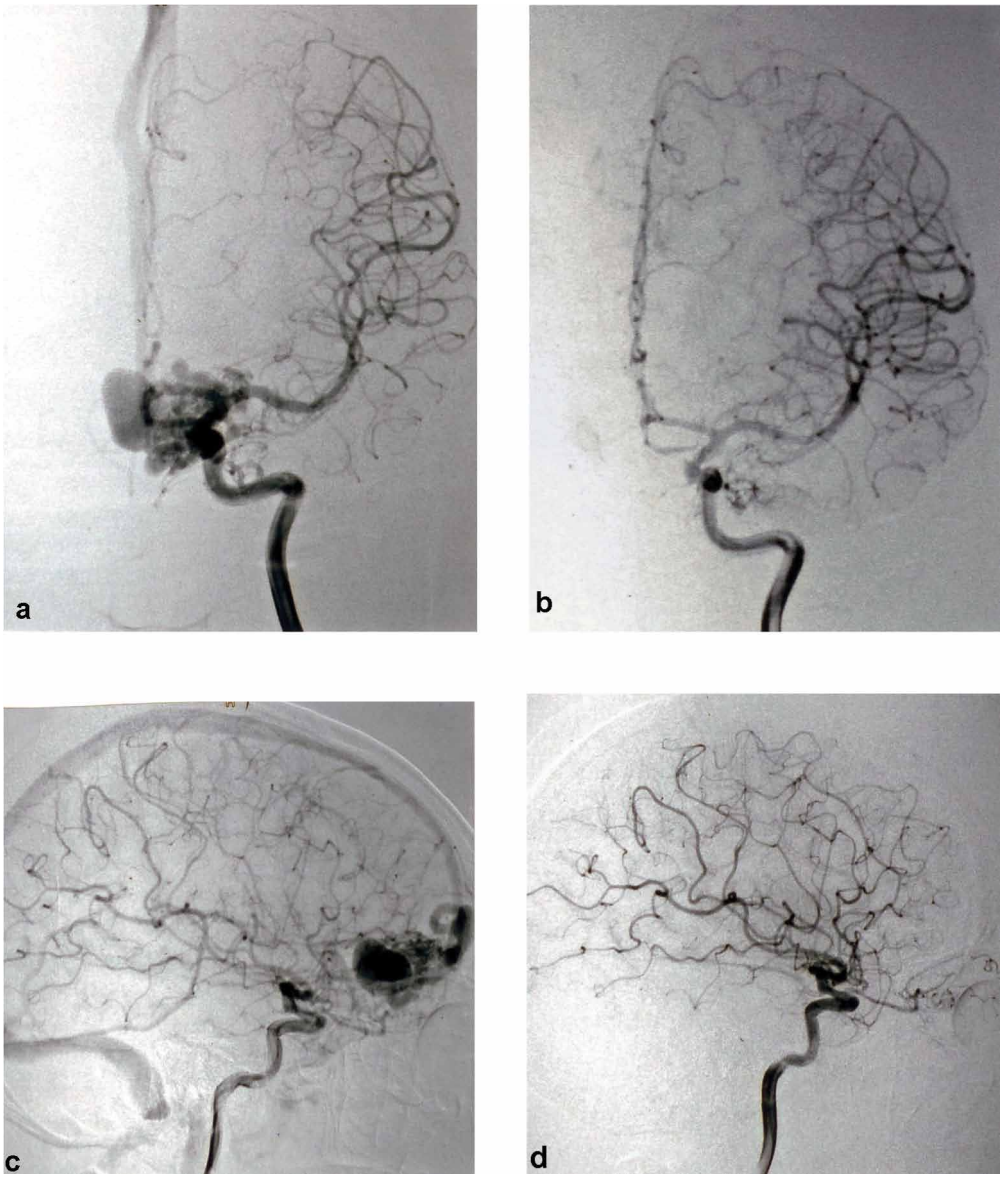

Figure 5.

Anteroposterior (a) and lateral (c) views of a left internal carotid artery angiogram that reveal the presence of a Spetzler-Martin Grade III arteriovenous malformation which was fed by the anterior cerebral arteries and drained in the anterior part of the superior sagittal sinus.
The postoperative left internal carotid angiography had demonstrated the complete resection of the arteriovenous malformation (b and d) (surgeon Leon Dănăilă). This 45-year-old woman presented a partial degradation of the sense of pudency and also several other symptoms which are characteristic for the deterioration of the orbital prefrontal cortex. The entire symptomatology had disappeared after the surgical treatment.

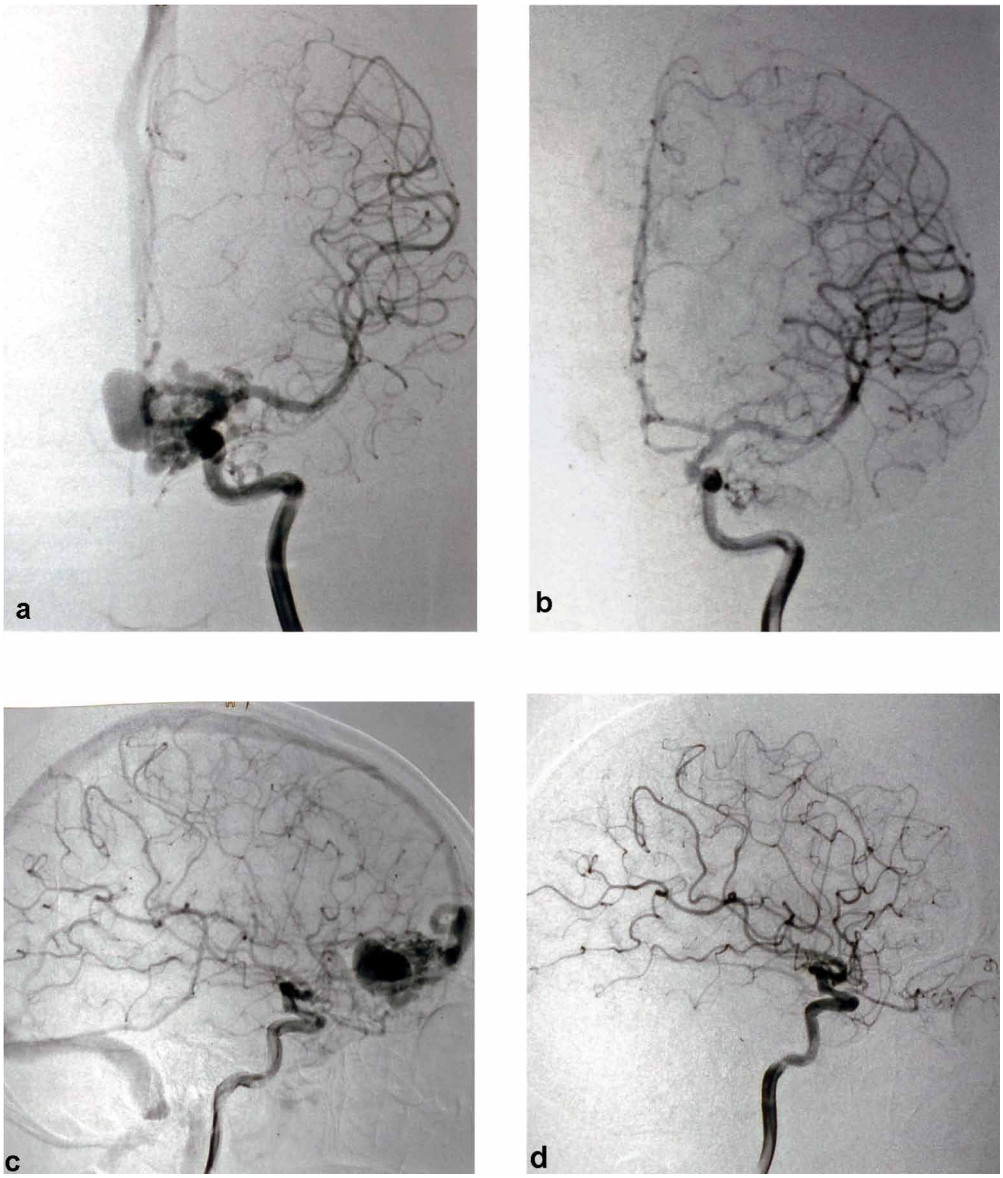

Figure 5.

Anteroposterior (a) and lateral (c) views of a left internal carotid artery angiogram that reveal the presence of a Spetzler-Martin Grade III arteriovenous malformation which was fed by the anterior cerebral arteries and drained in the anterior part of the superior sagittal sinus.
The postoperative left internal carotid angiography had demonstrated the complete resection of the arteriovenous malformation (b and d) (surgeon Leon Dănăilă). This 45-year-old woman presented a partial degradation of the sense of pudency and also several other symptoms which are characteristic for the deterioration of the orbital prefrontal cortex. The entire symptomatology had disappeared after the surgical treatment.

blic self-masturbation or exposing genital organs (Starkstein & Robinson 1997; Malloy et al. 1993; Miller et al., 1896).

3) The medial prefrontal syndrome

The anterior cingulated cortex occupies a mid-frontal position, and it is closely linked to the prefrontal cortex. The anterior cingulate cortex had been traditionally linked to emotion. According to Posner and Rothbart (1998), it also plays a role in the social development through the regulation of distress.

The hallmark feature of the medial apathetic syndrome is a severe reduction in spontaneity and motivation.

Thus, the patients with medial syndrome are able to generate internally organized plans for action, but they lack the impetus to carry them out. This syndrome is also characterized by a reduced interest in the environment (Dănăilă, 2018).

In general, the patient has a flattened affect, which is illustrated by a blunted facial expansion.

The overall alteration in motivation and in motor activity is a result of the lesions which involve the medial motor cortices (Morecraft and Yeterian, 2002, Dănăilă and Golu, 2006; Dănăilă, 2018).

The lesions that involve the pathways which connect the cortical areas located between, and just under the hemispheres with the drive and affective integration centres in the diencephalon are the most apt to affect the emotional and the social behaviour by dampening or nullifying altogether the capacities emotional experience as well as those for drive and motivation (Barrash et al, 2000; Dănăilă, 2019).

The patients who sustain damage at the level of the frontal areas of the brain, with the loss of the affective capacity, will have low drive states, even for the basic needs as those for food or drink; in those who are only moderately muted emotionally, the life-sustaining drives will remain intact, but the sexual interest might be reduced, along with the interest in initiating and maintaining the social or the vocational activities. Another deficit was the loss of the control of the urinary and rectal sphincters due to the involvement of the voluntary motor centres located in the paracentral area.

Cairns, in 1941, and Kreindler, Macovei, Cardas and Dănăilă, in 1966, had described the akinetic mutism which was produced by the lesions of the medial-basal prefrontal regions.

The clinical conditions are characterized by absolute mutism and complete immobility, with the exception of the eyes which are kept open and move in all directions. The patient appears to be awake and maintains a sleep-wake cycle, but there cannot be established any communications with the patient, through either painful or auditory stimuli.

Consequently, we can assert that the medial surface of the prefrontal lobe plays a minor role in the sense of decency, which is nothing more than the feeling of pudency.

The most common causes of the medial prefrontal syndrome are represented by the midline meningiomas of the falx cerebri, the infarctions following the occlusion of the anterior cerebral artery and of its branches, multiple sclerosis, the infections of the central nervous system, as well as the frontotemporal dementia (Dănăilă et al., 1996).

Conclusions

Nevertheless, the prefrontal cortex is the most distinctively "cognitive" and behavioural part of the brain.

The prefrontal cortex is the largest in humans, and it distinguishes our species from other primates.

In addition, the prefrontal cortex has regions for the emotional, and personality processes, as well as for pudency (sense of decency) and social cognition, thus empowering the individuals to know "how to behave".

By simply considering the large diversity of the connections of the prefrontal area, it is difficult to conceive that a lesion of any area, either single or in combination, should result in a clinical picture which we could consider to be unique for all the cases with an anatomically identical lesion (Dănăilă, 2018).

However, there are certain groups of symptoms which tend to occur together after the occurrence of a prefrontal lesion, and they differ depending on the location and the magnitude of the lesion (Dănăilă, 2018). The lesions located within the extended cortical or subcortical neural system might produce functional deficits which are similar to those which occur when the damage is isolated within a specific prefrontal region.

Therefore, the patients with lesions which involve regions of the basal ganglia or of the mediodorsal nucleus of the thalamus that are topographically interconnected with the dorsolateral prefrontal cortex might present with behavioural disorders that are essentially the same as those which occur in the patients with damage restricted to the dorsolateral prefrontal cortex.

Lesions located in the prefrontal cerebral cortex modify the sexual behavior, and the appearance of penetration and ejaculation dysfunctions had been previously demonstrated in rats. The pathologic processes generated inside the prefrontal cortex also take responsibility for determining the normal erotic ideas and images. The lesions in the frontal orbital cortex initiate the public deviant sexual behavior of the respective person - like showing their genitals in a social environment, public automasturbation, etc.

CONFLICT OF INTERESTS

The authors declare that there is no conflict of interest

REFERENCES

1. Agmo, A., & Villalpando, A.- Central nervous stimulants facilitate sexual behavior in male rats with medial prefrontal cortex lesions. Brain Research, 696(1–2), 187–193, 1995.
2. Barrash J, Tranel D, Anderson SW. - Acquired personality disturbances associated with bilateral damage to the venality disturbances associated with bilateral damage to the ventromedial prefrontal region. Developmental Neuropsychology, Vol. 18; 355 - 381, 2000.
3. Bechara A, Damasio H, Damasio AR, Lee GP. - Different contributions of the human amygdala and ventromedial prefrontal cortex to decision making. Journal of Neuroscience, Vol. 19; 5473 - 5481, 1999.
4. Cairns H, et al. - Akinetic mutism with an epidermoid cyst of the 3rd ventricle. Brain, Vol. 64; 272 - 290, 1941.
5. Dănăilă L. - Normal and Pathological Venous System of the Brain. The Publishing House of the Romanian Academy, Bucharest, 2016.
6. Dănăilă L. - Functional Neuroanatomy of the Brain. First, Second and Third Parts. Pro Universitaria, Bucuresti, 2018.
7. Dănăilă L. - The Cells of the Brain. A review book. Editura Medicala, 2018.
8. Dănăilă L, Golu M. - Psychiatric Surgery. Possibilities and limits. Ed. Academiei Republicii Socialiste România, 1988.
9. Dănăilă L, Golu M. - Tratat de Neuropsihologie Vol. 2 Editura Medicala, 2018.
10. Dănăilă L, Pascu ML. - Contribution to the Understanding of the Neural Bases of the Consciousness. In: Terry Lichtor, Clinical Management and Evolving Novel Therapeutic Strategies for Patients with Brain Tumors. INTECH, Croatia, 2013.
11. Dănăilă L, Gheorghe MD, Ploaie P. - Boala Alzheimer. Editura Militara, București 1996.
12. Francis, S., Rolls, E. T., Bowtell, R., McGlone, F., O'Doherty, J., Browning, A., Clare, S., & Smith, E.- The representation of pleasant touch in the brain and its relationship with taste and olfactory areas. Neuroreport, 10(3), 453–459, (1999).
13. Kreindler A, Macovei M, Cardas M, Dănăilă L. - Akinetic mutism. Anatomo-clinical considerations. St. Cerc Neurol, Vol 91; 349 - 360, 1966.
14. Malloy, P., Bihrle, A., & Duffy, J.- The orbitomedial frontal syndrome. Archives of Clinical Neuropsychology, 8(3), 185–201,1993.
15. Miller, B. L., Cummings, J. L., McIntyre, H., Ebers, G., & Grode, M.- Hypersexuality or altered sexual preference following brain injury. Journal of Neurology, Neurosurgery, and Psychiatry, 49(8), 867–873, 1986.
16. Morecraft RJ, Yeterian EH - Prefrontal cortex. In: VS Ramachandran (ed), Encyclopedia of Human Brain, Vol. 4, Academic Press, Amsterdam, Boston, London, 11 - 25, 2002.
17. Nițescu V. Treaty of Clinical Sexology, The Publishing House of the Romanian Academy, Bucharest, 18- 32, 2018.
18. Redoute, J., Stoleru, S., Gregoire, M. C., Costes, N., Cinotti, L., Lavenne, F., Forest, M. G., & Pujol, J. F.- Brain processing of visual sexual stimuli in human males. Human Brain Mapping, 11(3), 162–177, 2000.
19. Postner MI, Rothbart MK. - Attention, self-regulation and consciousness. Philosophical Transaction of the Royal Society of London. Series B: Biological Sciences, Vol. 353; 915-927, 1998.
20. Starkstein, S. E., & Robinson, R. G.- Mechanism of disinhibition after brain lesions. Journal of Nervours and Mental Disease, 185(2), 108–114, 1997.
21. Yamanouchi, K., & Arai, Y.- Possible role of cingulate cortex in regulating sexual behavior in male rats: Effects of lesions and cuts. Endocrinology Japan, 39(3), 229–234, 1992.

Original article

Received: 14.02.2019
Accepted: 14.03.2019

INTERRELATION BETWEEN THE MALE'S AGE, THE QUALITY OF THE SEMINAL FLUID AND FECUNDITY

COURIER TITLE: The properties of the semen at different ages

[1]Andy PETROIANU*
[1]Marco Antônio BARRETO de MELO
[1]Luciana MAGALHÃES de ALMEIDA
[2]Valentin NITESCU

[1] Department of Surgery, Faculty of Medicine, Federal University of Minas Gerais, Brazil
[2] Department of Surgery, „Clinical Hospital Dr.I. Cantacuzino", Bucharest, Romania

Abstract:

The morphophysiological changes of the seminal fluid components that negatively influence male fertility are determined by specific genital pathology and / or the decrease of the biological potential in relation to the age.

Establishing the age of the man in which the most normal spermatozoa structures are found is the subject of the study.

The age considered favorable for the actual procreation of the male was considered to be between 20- 60 years. In this study it was concluded that most of the normal spermatozoa forms were found in the age group of men who were 41-50 years old.

We consider the cases of procreation of adolescents under the age of 20, or of the seniors over the age of 70-80 to be special, from whom optimal spermatozoa are selected for fertilization (♂ 82 years old).

Keywords:

spermatozoa, age, fertility

INTRODUCTION

The seminal plasma consists of secretions of the epididymis, the ductus deferens, the seminal vesicle, the prostate, the bulbo-urethral glands and the testicular secretions, ensuring the fertility, survival and motility of the spermatozoa.

The seminal fluid contains proteins, fats, carbohydrates, enzymes, hormones, citric acid, carnitine, minerals and prostaglandins, each one having a specific role and value for fertility, such as the spermatozoa secreted by the convoluted seminiferous tubules bring the specific genetic background [15].

In fact, this diversity of shape and substance of abnormal spermatozoa, that appears in elderly, is responsible for abortions, pre- and postnatal mortality of the conception product, infertility. It is known that with the advancing age, male sexual relations rise due to the decrease in biological potential and associated diseases (V.Nitescu), the ejaculate volume is lower and the morphophysiology of the sperm changes from normality.

However, in studies comparing seminal characteristics of fertile fathers of over 60 years of age and those of less than 35 years of age, the older men showed a higher spermatozoid density with lower motility.

The results of these papers presented no difference in either the seminal volume or the concentration of normal spermatozoid morphology [1,2,3,4,5]. Sperm deficiencies occur in 30% of infertile men [3,6,7,8].

Some studies have reported a reduction in the daily spermatogenesis in aging groups. This condition is associated with an increase in serum gonadotrophin and a drop in testosterone levels [1,8,9,10,11]. Testicular biopsies and the radioimmunoassay of the gonadotrophic hormone indicate a lower Sertoli cells function, less cytoplasm in the Leydig cells, as well as diminished and thickened *lamina propria of seminiferous tubules* [5,8,10,11,12,13,14].

Although semen quality seems to decline with age in elderly men, spermatozoid characteristics remain normal, according to World Health Organization (WHO) standards [1,2,4,16,17]. In cases of infertility, the aging effect on the quantity of semen can be significant enough to impact the sperm function [3]. The reduction in semen quality, along with a reduced sex life, may have a negative effect on a couple's fertility [3,5].

Due to scarce and controversial data concerning semen related with age, the present study sought to assess sperm characteristics at different ages in an attempt to analyze the relationship between male age and spermatozoid forms.

Correspondence to: [1]Professor Andy Petroianu, Avenida Afonso Pena, 1626 - apto. 1901
Belo Horizonte, MG 30130-005, Brazil
Phone / fax number: 55 - 31 - 3274-7744 OR 55 - 31 - 98884-9192,
E-mail: petroian@gmail.com

METHODS

This study was performed according to the Helsinki Declaration and was approved by the Committee of Ethics in Research of the Federal University of Minas Gerais, Brazil, under protocol number 0429/15. All volunteers agreed to participate in this investigation, and signed the Informed Consent Form.

The semen of 80 healthy men, between 21 and 60 years of age, were studied after three to five days of sexual abstinence. This period was established based on the New 2010 WHO Standards (5th edition) for the Evaluation of Human Semen recommendations [2,16,17,18,19]. Volunteers were distributed into four age groups (n = 20): 21 to 30 (23 ± 5), 31 to 40 (33 ± 4), 41 to 50 (45 ± 2) and 51 to 60 (58 ± 3) years of age.

The volunteers were selected by directed anamnesis referring to sexual background (frequency of sexual activity, erectile or ejaculation disorders and previous paternity). Men with previous urological disease or endocrine disorders, such as diabetes mellitus; those using any drug; those who were infertile or with a family history of infertility; or those presenting any other sexual disturbance were not included in this study. The presence of leukocytospermia in the sperm specimen excluded the patient from this investigation.

A single specimen of sperm from each volunteer was collected into a sterile flask, which was immediately hermetically closed. Volume, aspect, odor, viscosity and pH of the seminal fluid were assessed immediately after sperm harvesting. The microscopic characteristics of the spermatozoids were defined approximately one hour later, the characterization of which included total motility at room temperature of 26 ºC and morphological aspects.

After diluting the semen in 1:20 solution (0.1 mL sperm in 1.9 mL of a 0.9% saline solution), sperm cells were counted in a Neubauer chamber by using an optical binocular microscope. The counts of the morphologic spermatozoa were done blindy and included the five chamber quadrants; the four lateral quadrants, used in hematology for leukocytes counts; plus the central area, used for erythrocyte counts. The total spermatozoid counts were multiplied by one million to obtain the exact number of spermatozoids per mL. According to morphology, spermatozoids were classified as normal (oval) or abnormal (tapered, round, amorphous, immature, double-headed, double-tailed, macrocephalic or microcephalic) [3,14,16]

The descriptive method for the mean and the standard error of the mean (SEM) was used for statistical analysis. Results were compared using the analysis of variance (ANOVA), followed by the Tukey-Kramer test for multiple comparisons. Bonferroni correction was applied to ANOVA. Differences were considered significant for values amounting to $p < 0.05$.

RESULTS

No difference in semen volume, sperm concentration or sperm morphology was observed among the groups. No difference was found among *sui generis* smell, light gray color, viscosity within the normality limits and pH = 7. The ejaculated volume varied between 2.0 and 3.2 (mean = 2.5 ± 0.2) ml. A higher concentration of spermatozoids was found in the two groups of over 41 years of age when compared to the other two groups. (20 – 30:

83 ± 49 X 10^6 / ml, 31 – 40: 76 ± 46 X 10^6 / ml, 41 – 50: 105 ± 49 X 10^6 / ml, 51 – 60: 173 ± 25 X 10^6 / ml). No sperm specimen with leukocytospermia was found in this study.

The microscopic analysis one hour after seminal fluid harvesting identified a similar percentage of mobile spermatozoids in the four groups (20 – 30: 70.0 %, 31 – 40: 69.1 %, 41 – 50: 76.7 %, 51 – 60: 75.4 %). However, the normal oval spermatozoids were more frequent in the group of 41 to 50 years of age when compared to the other three groups (p = 0.03) (1 – 30: 27.8 ± 4.4 %, 31 – 40: 28.2 ± 6.3 %, 41 – 50: 38.0 ± 8.1 %, 51 – 60: 30.4 ± 7.7 %). Plasma membrane integrity was preserved in all spermatozoids of all cases.

DISCUSSION

Previous inconclusive and even inconsistent studies have reported that an increased male age is significantly associated with a decrease in semen volume, a decline in morphologically normal spermatozoa, as well as a reduction in progressive motility and sperm concentrations [1,2,4,15,16]. Semen quality is an indirect measure of fertility; however, the fertility of a given semen sample cannot be established with certainty. Some comparative studies with healthy subjects showed that spermatogenic capacity is higher after three to five days of sexual abstinence [2,3,15,16,18]. By contrast, more immature spermatozoids with lower motility have been described during shorter intervals. In the present study, the sperm from all volunteers was harvested after three to five days of sexual abstinence.

Atherosclerotic vascular disturbance is associated with an impairment in the testicular blood supply, causing parenchymal loss and sclerosis of the seminiferous tubules. This sequence of events is most commonly due to autoimmune inflammatory testicular atrophy, and has been described as a cause of reduction in spermatogenesis and a decrease in libido with advancing age [2,10,13,19,20]. Prostatic disorders are also related to a reduction in seminal fluid in elderly men [13,20]. Changes in the biochemistry of human semen have been reported with aging, showing decreases in the concentrations of fructose, kallikrein and prostate specific antigen (PSA), as well as raised liquefaction times. Recent studies have shown sperm DNA damage is significantly higher in older men [21,22]. These alterations could cause age-related declines in sperm motility and fertilizing ability [2,4,8].

In this study, no volunteer complained of any sexual abnormality and the seminal fluid presented normal physical and chemical characteristics. Furthermore, the concentration of a

normal (oval) spermatozoid shape, considered ideal for fecundation, was higher in men over 41 years of age. No volunteers of 60 years of age or older were examined in this study due to the difficulty of finding men with no health disorder and who agreed to be included in this study. The analysis of the sperm motility at room temperature of 26ºC was not ideal. A lower temperature comparing with the 36ºC – 37ºC of the body environment could inhibit the motility, but the temperature was the same during the assessment of all spermatozoa, thereafter a possible error in results was constant for all groups.

The results of this work conflict with the data from prior literature regarding sperma-

tozoid characteristics. According to these results, aging up to 60 years of age improves the aspect and motility of the spermatozoids with no negative influence on a man's seminal fluid. Additionally, the lowest rate of abnormal spermatozoid shapes found in men over 41 years of age suggests that they may in fact have a higher rate of fertility.

CONCLUSION

More normal forms of spermatozoids are found between 41 and 50 years of age.

ACKNOWLEDGMENTS

The authors gratefully thank the Research Support Foundation of the State of Minas Gerais (FAPEMIG), the National Council for Scientific and Technological Development (CNPq) and the Dean's Office for Research (Pró-reitoria de Pesquisa) at UFMG for their financial support.

CONFLICT OF INTERESTS

The authors declare no conflict of interest related to this study and its publication.

REFERENCES

1. Matsuda Y, Shimokawa KI, Katayama M, Shimuzu H, Chiba R. Action of physiologically active materials in human semen during aging. Arch Androl 2004; 50: 131-7.
2. Levitas E, Lunenfeld E, Weisz N, Friger M, Potashnik G. Relationship between age and semen parameters in men with normal sperm concentration: analysis of 6022 semen samples. Andrologia. 2007; 39: 45-50.
3. Hossain MM, Fatima P, Rahman D, Hossain HB. Semen parameters at different age groups of male partners of infertile couples. Mymensingh Med J. 2012; 2: 306-15
4. Cornwallis CK, Dean R, Pizzari T. Sex-specific patterns of aging in sexual ornaments and gametes. Am Nat. 2014; 184: E66-78.
5. Zavos PM, Kaskar K, Correa JR, Sikka SC. Seminal characteristics and sexual behavior in men of different age groups: is there an aging effect? Asian J Androl. 2006; 8:337-41
6. Practice Committee of the American Society for Reproductive Medicine. Definition of “infertility”. Fertil Steril. 2006; 86 (5 Suppl): S228.
7. Tesarik J, Mendoza C. Treatment of severe male infertility by micromanipulation-assisted fertilization: an update. Front Biosci. 2007; 12: 105-14.
8. Patel DP, Brant WO, Myers JB, Zhang C, Presson AP, Johnstone EB, Dorais JA, Aston KI, Carrell DT, Hotaling JM. Sperm concentration is poorly associated with hypoandrogenism in infertile men. Urology. 2015; 85: 1062-7.
9. Schlosser J, Nakib I, Carre-Pigeon F, Staerman F. Male infertility: management strategies. Ann Urol. 2007; 41: 6-11.
10. Dakouane-Giudicelli M, Bergere M, Albert M, Serazin V, Rouillac-Le Sciellour C, Vialard F, et al. Late paternity: spermatogenetic aspects. Gynecol Obstet Fertil. 2006; 34: 855-9.
11. Gleicher N, Barad D. DHEA and testosterone in the elderly. N Engl J Med. 2007; 356: 636-7.
12. Lacombe A, Lelievre V, Roselli CE, Salameh W, Lue YH, Lawson G, et al. A neuropeptide at the origin of testicular aging? Med Sci (Paris). 2006; 22: 809-11.
13. Johnson L, Abdo JG, Petty CS, Neaves WB. Effect of age on the composition of seminiferous tubular boundary tissue and on the volume of each component in humans. Fertil Steril. 1988; 49: 1045-50.
14. Merino G, Carranza-Lira S. Semen characteristics, endocrine profiles, and testicular biopsies of infertile men of different ages. Arch Androl. 1995; 35: 219-24.
15. Nițescu V. Treaty of Clinical Sexology, The Publishing House of the Romanian Academy, Bucharest, 87- 99, 2018.
16. Elzanaty S, Malm J. Comparison of semen parameters in samples collected by masturbation at a clinic and at home. Fertil Steril. 2008; 89: 1718-22.
17. Morshedi M. New 2010 WHO Standards for the Evaluation of Human Semen. 5th Ed. 2010; College of Reproductive Biology, Norfolk, USA.
18. Gupta G, Jangir S, Sharma VL. Targeting post-ejaculation sperm for value-added contraception. Curr Mol Pharmacol. 2014; 7: 167-74.
19. Richthoff J, Spano M, Giwercman YL, Frohm B, Jepson K, Malm J, et al. The impact of testicular and accessory sex gland function on sperm chromatin integrity as assessed by the sperm chromatin structure assay (SCSA). Hum Reprod. 2002; 17: 3162-9.
20. Buwe A, Guttenbach M, Schmid M. Effect of paternal age on the frequency of cytogenetic abnormalities in human spermatozoa. Cytogenet Genome Res. 2005; 1: 213-28.
21. Homonnai ZT, Fainman N, David MP, Paz G. Semen quality and sex hormone pattern of 39 middle aged men. Andrologia. 1982; 14(2): 164-170.
22. Moskovtsev SI, Willis J, Mullen JB Age-related decline in sperm deoxyribonucleic acid integrity in patients evaluated for male infertility. Fertil Steril. 2006; 85: 496-499.
23. Plastira K, Msaouel P, Angelopoulou R, Zanioti K, Plastiras A, Pothos A, Bolaris S, Paparisteidis N, Mantas D. The effects of age on DNA fragmentation, chromatin packaging and conventional semen parameters in spermatozoa of oligoasthenoteratozoospermic patients. J Assist Reprod Genet. 2007; 24: 437-443.

Review

Received: 13.02.2019
Accepted: 14.03.2019

PRESERVATION OF SEXUAL FUNCTION IN RECTAL SURGERY

Mircea BEURAN
Carol Davila University of Medicine and Pharmacy, Bucharest
Emergency Hospital of Bucharest, Romania

„Keeping and renewing is almost as noble as creating"

Voltaire –" Philosophic dictionary"

Surgical anatomy of the rectum

Rectal surgery has been traditionally associated with sexual and urinary complications [1,2]. This conception has changed significantly over the past decades, with the addition of evidence that an anatomical dissection following embryological plans leads to similar oncological results but with a significant increase in quality of life. A decisive step was taken by Bill Heald, who introduced the total mesorectal excision for the treatment of rectal cancer in 1979 [3]. In 1991, Warren Enker detailed the preservation of autonomic nerves in the total excision of mesorectum [4]. Sympathetic innervation produces relaxation of smooth rectal muscles and muscle contraction of the internal anal sphincter (IAS). Parasympathetic stimulation produces contraction of rectal smooth muscle and relaxation of IAS. The external anal sphincter (EAS) is torn by the shy nerve and is volun-

Corresponding author: Prof. Univ. Dr. Mircea Beuran FACS "Carol Davila" University of Medicine and Pharmacy, Bucharest, Emergency Hospital of Bucharest, Romania, Calea Floreasca Nr. 8, Sector 1, Bucharest, Romania, E-mail: drbeuranmircea@yahoo.com

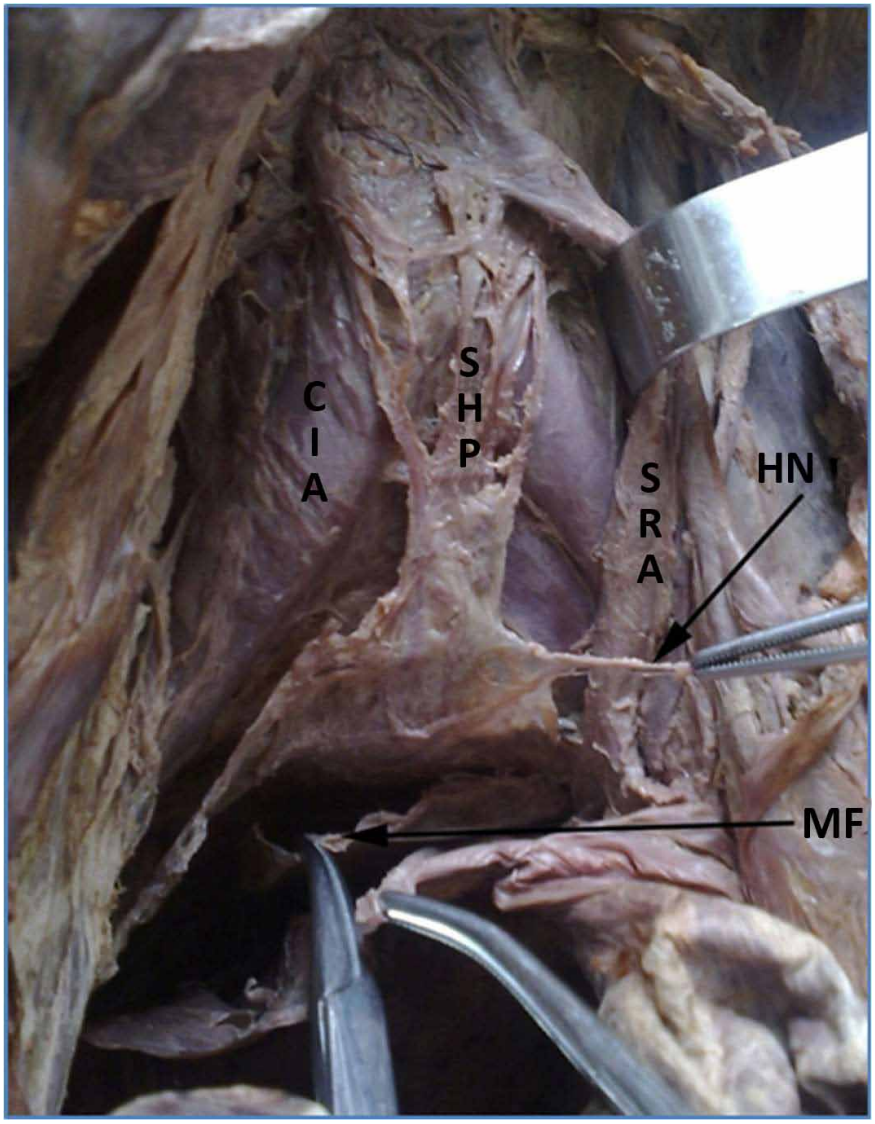

Figure 1:

Cadaver dissection. SHP – superior hypogastric plexus, HN – hypogastric nerve, MF – mesorectal fascia, SRA – superior rectal artery, CIA – common iliac artery (Picture from Emergency Hospital of Bucharest and Carol Davila University of Medicine and Pharmacy collection [1,2]).

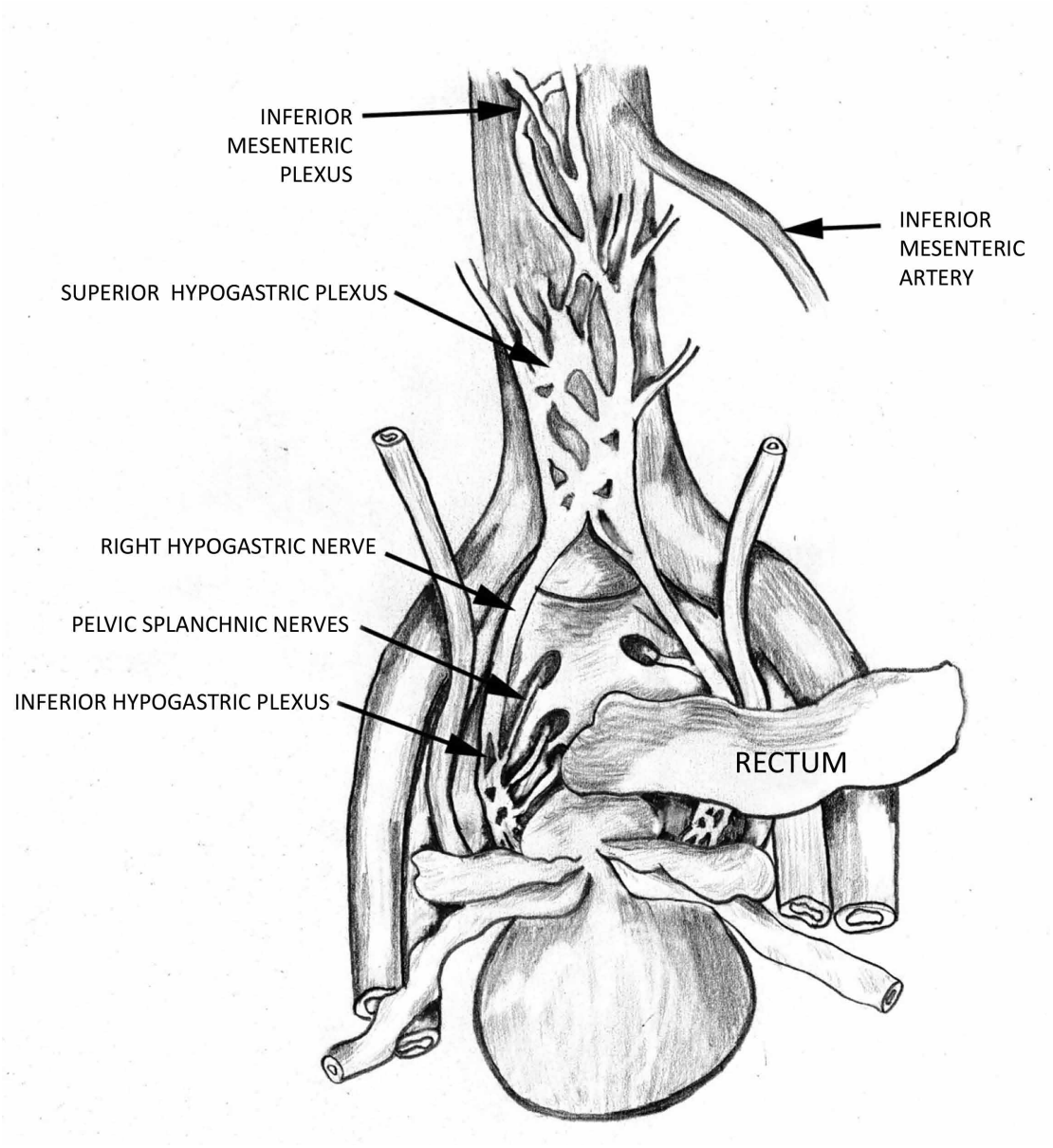

Figure 2:

Schematic representation of the pelvic vegetative nervous plexus (Image from the Emergency Hospital of Bucharest and Carol Davila University of Medicine and Pharmacy collections [1,2]).

tarily controlled. The nervous structures that innervate the pelvic organs can be organized into three structures: the superior hypogastric plexus, the hypogastric nerves and the lower hypogastric plexus [1,2]. The Superior Hypogastric Plexus (SHP) is a network of sympathetic nerve fibers, located anteriorly of the bifurcation of the aorta, sacral promontorium and between the common iliac arteries. This plexus receives sympathetic fibers from the aortic plexus (localized superiorly) and L3, L4 [1,2] (Fig.1).

This SHP can be damaged during lymphadenectomy, concurrently with dissection and ligation at the origin of the inferior mesenteric artery. SHP is continued to the inferior and lateral with 2 hypogastric nerves. Hypogastric nerves (HN) continue inferiorly SHP (Fig.2).

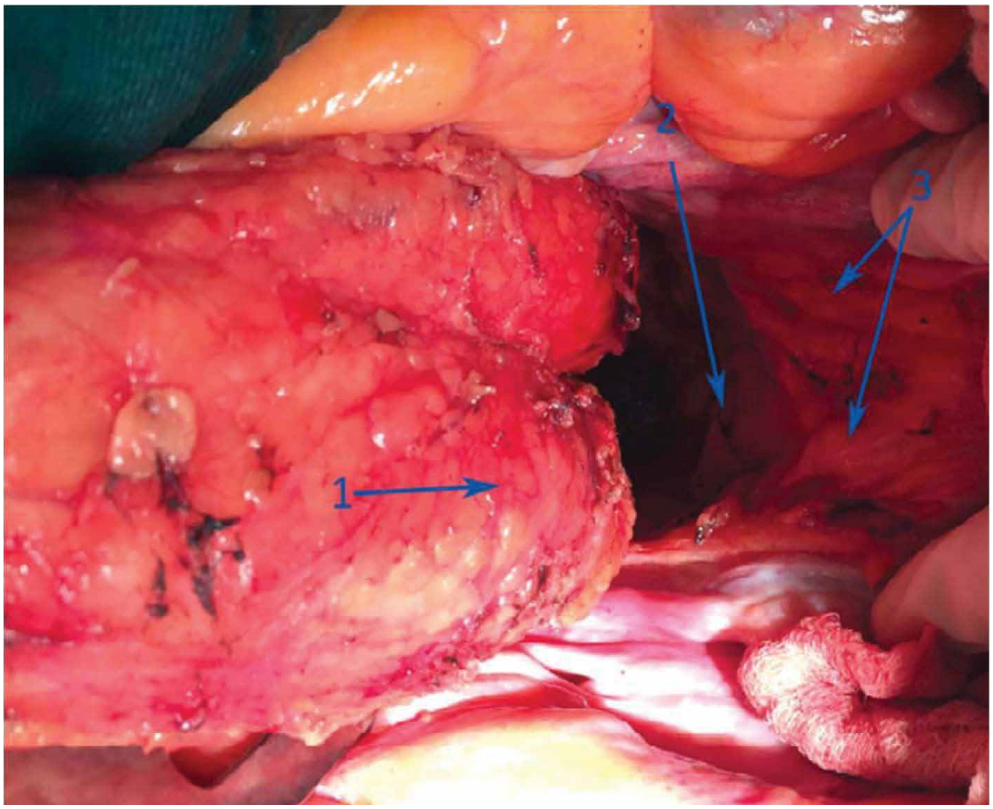

Figure 3:

Intraoperative aspect of the posterior dissection at the mesorectal fascia (1), anteriorly of the presacral fascia (2), during low anterior rectal resection. 3 – hypogastric nerves (Image from the Emergency Hospital of Bucharest and Carol Davila University of Medicine and Pharmacy collections [1,2]).

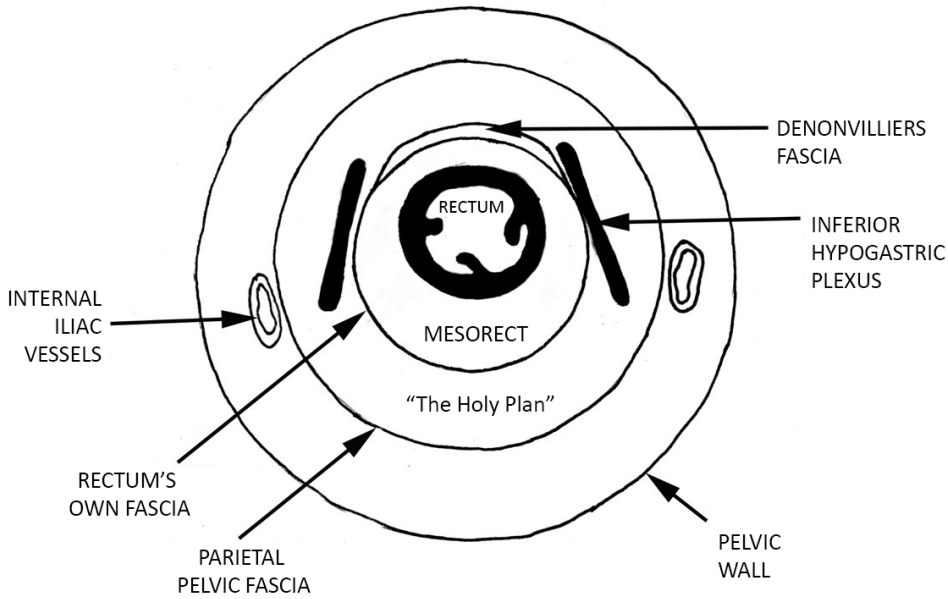

Figure 4:

Schematic representation of the spaces around the rectum. The pelvic fascia can be compared with the leaves of an onion (Image from Emergency Hospital of Bucharest and Carol Davila University of Medicine and Pharmacy collection) [1,2].

These nerves are formed predominantly from sympathetic fibers. At the sacral promontorium, the two hypogastric nerves are located 1 cm lateral of the median line. They continue inferiorly, parallel with the ureter, and are located 1-2 cm medial to it. Distally, at the level of the pelvic side walls, HN are joined with the pelvic splanchnic nerves (parasympathetic) to form the inferior hypogastric plexus. [1,2]. The hypogastric nerves are located external and postero-laterally by the rectum fascia – mesorectal fascia and anterior to the parietal endopelvic fascia (Fig.3). They are adherent to the rectum's own fascia and must be removed by visual control to the lateral, during the posterior dissection of the rectum. Inferior hypogastric plexus (IHP) is a nerve tissue blade oriented in a semi-planar plane between the rectum's own fascia an the parietal endopelvic fascia.

IHP is found on the antero-lateral face of the mesorectum, its middle being in the around the seminal vesicle. IHP is 4-5 cm long and is crossed by numerous vessels that run

to the rectum, bladder and internal genital organs. In men, IHP is located laterally from the seminal vesicles, prostate and bladder. In woman, IHP is located laterally from the cervix, vaginal fornix, bladder and sometimes extends into the broad ligaments of the uterus [1,2]. IHP is made up of sympathetic fibers that come from the hypogastric nerves and parasympathetic fibers that come from the pelvic splanchnic nerves or the erector nerves. Erector nerves originate at S2, S3, S4 levels. At the origin, erector nerves, are found in exterior of the parietal endopelvic fascia, but medial to internal iliac vessels (Fig.4). 3-4 cm anterior from their origin, posterior of the seminal vesicles, erector nerves perforate the parietal fascia from the lateral to the medial to end in the inferior hypogastric plexus. IHP continues to the anterior with branches that forms Walsh neurovascular fascicles.

These structures will innervate corpus cavernous and prostate. At the tip of the prostate, these structures approach the prostatic capsule at 5 and 7 o'clock. Ejaculatory function depends on the sympathetic component. Erection is produced by both parasympathetic (arteriolar vasodilatation) and sympathetic (inhibits vasoconstriction) [1,2]. Erection is under sacral parasympathetic control. Ejaculation is controlled by a complex mechanism driven primarily by lumbar sympathetic centers, and secondly by sacral parasympathetic centers. Sympathetic centers ensure contraction of the smooth muscles of the seminal vesicles, deferent duct, epididymis, as well as the bladder internal sphincter. Sacral parasympathetic centers also participate in this reflex by contracting perineal and urethral muscles and relaxing the bladder external sphincter [5].

Must be remembered that the left colon receives retrograde parasympathetic innervation from S2, S3 and S4. These fibers take the path through IHP, HN, SHP, inferior mesenteric plexus and with the branches of the inferior mesenteric artery reach the left colon. Some fibers go directly retroperitoneal to the left colon, without accompanying the branches of the inferior mesenteric [1,2].

Rectal resections for malignant disease

In modern rectal surgery, the complete excision of mesorectum is a desideratum for the malignant pathology of this segment of the digestive tract. In recent years, minimally invasive surgery has proven effective in curative treatment of rectal neoplasia, but open surgery remains the primary pathway for treating this pathology. The preservation of the pelvic nerves involved in pelvic statics, sphincter control and sexual function is also one of the main objectives [6]well established in the modern curative surgery of rectal cancer, needs further investigation, especially with regards to the preservation technic of the autonomous abdominopelvic innervation currently used to prevent or reduce the urogenital sequelae. The Authors offer a perspective study over the recovery of sexual activity in a homogeneous group of 32 male patients submitted, because of cancer, to restorative proctectomy, with anatomical preparation of the hypogastric and sacral plexus. The criteria for eligibility were the followings: male under 70 years of age, excision of the primary rectal cancer with coloanal or colo-rectal anastomosis performed at less than

5 cm from the anal verge, staging not more than T3N2M0, without previous RT or other pelvic operations and without protective enterostomy, nor local or systemic recurrences during the follow up period. The functional results obtained on the basis of a questionnaire, filled in quarterly by the patients as well as their partners for at least a year, three months after the operation were: lack of sexual disorders in 37.5%, reduction of the sexual activity (partial erection, lack of ejaculation, anorgasmy. A study published in 1999 by Prete et al. reported that sexual dysfunction occurred in 37.5% of cases at 3 months (incomplete erection, absence of ejaculation or anorgasmia), but at one year, 65.6% of the patients had normal sexual activity, in low anterior rectal resection with total mesorectum excision (TME) with preservation of autonomic nerves [6]well established in the modern curative surgery of rectal cancer, needs further investigation, especially with regards to the preservation technic of the autonomous abdominopelvic innervation currently used to prevent or reduce the urogenital sequelae. The Authors offer a perspective study over the recovery of sexual activity in a homogeneous group of 32 male patients submitted, because of cancer, to restorative proctectomy, with anatomical preparation of the hypogastric and sacral plexus. The criteria for eligibility were the followings: male under 70 years of age, excision of the primary rectal cancer with coloanal or colo-rectal anastomosis performed at less than 5 cm from the anal verge, staging not more than T3N2M0, without previous RT or other pelvic operations and without protective enterostomy, nor local or systemic recurrences during the follow up period. The functional results obtained on the basis of a questionnaire, filled in quarterly by the patients as well as their partners for at least a year, three months after the operation were: lack of sexual disorders in 37.5%, reduction of the sexual activity (partial erection, lack of ejaculation, anorgasmy.

In the literature, resection of rectal tumors with oncological limits is considered to be associated with a significant rate of sexual and urinary dysfunction. However, current surgery attempts to obtain both the excision within the oncological safety limits and the preservation of these functions. Procard et al. published in 2002 a study of 20 patients (13 men and 7 women) with rectal neoplasm with surgery per primam with complete excision of mesorectum, but with intraoperative identification and preservation of hypogastric and sacral splanchnic nerves. The tumors were staged according to the Astler-Coller classification, A1 and A2 - 3 cases, B1 – 7 cases, B2 – 2 cases, C2 – 1 case and D – 1 case. No postoperative urinary dysfunction or urodynamic changes were observed in any patient. 4 of the 7 women were sexually active preoperatively. Sexual activity and the ability to obtain orgasm have not been postoperatively altered, at one-year follow-up. 9 of the 13 men were potent preoperatively. Sexual activity and potency were not altered postoperatively in these men at one-year follow-up. Retrograde ejaculation was reported in one case. The authors also mentioned the decrease in intensity of erection in 4 patients at 3 months postoperatively, but with one-year remission [7].

However, it is known that cancer can spread along the nerve pathways. Based on this theorem, Maeda and colleagues conducted a prospective study in 2002 involving 50 patients. In 19 of these, preoperative, intrarectal, activated carbon particles were injected, so

intraoperatively the autonomic nerves were dissected from the adjacent connective tissue and microscopically analyzed; lymph nodes located along the axial and lateral drainage pathways were also microscopically analyzed. In 47 of the 50 cases, lymph nodes were found in connective tissue adjacent to the nerves. 2 of the patients showed positive nodules along the preaortic and presacral plexus, and one patient with positive lymph nodes at pelvic plexus were with unfavorable prognosis despite nerve resection. The authors conclude that in the case of tumors located cranially from the peritoneum reflection, lymphatic drainage is performed preferentially along the axial and lateral pathways, but in the case of those located lower than the reflection of peritoneum it disseminates along the nerve pathways, so in these cases, the complete excision of mesorectum with nerve preservation is not oncological safe [8].

In 2004, Tsunoda et al. conducted a retrospective study of 129 patients with rectal cancer who underwent two types of nerve-sparinginterventi-on. In 61 cases the superior hypogastric plexus an both hypogastric nerves were resected, and in 68 cases they were preserved. Pelvic plexus was preserved in all cases. Survival rates and local relapse rates between the two batches were compared. At 3 years, the relapse rate was 13.1% for the first batch and 10.3% for the second batch. The distance metastasis rate and the survival rate at 5 years were 23% and 61.6% respectively in patients with nerve resection and 16.2 % and 77.4% in those with nerve preservation. The authors conclusion was that there was no statistically significant difference between the two types of surgery [9].

In 2014, Ma G. et al. published an article on anatomical bases in low anterior rectal resection for the preservasion of autonomic nerves. They describe the pattern and distribution of pelvic autonomic nerves and their relationship with pelvic fascias in 12 men. Hypogastric nerves have a tract between the anterior sacral fascia and the inferior hypogastric plexus at the level of parietal fascia. Inferior hypogastric plexus crosses the Denonvilliers fascia fusion line with the parietal fascia at 10 and 2 a clock of the rectum and joins the urogenital vessels. The authors believe that the dissection safety plan should be chosen between the rectal fascia and the anterior sacral fascia in the posterior and lateral dissection of the rectum, with increased attention at 10 and 2 a clock of the rectum for the preservation of the neurovascular bundles, between the Denonvilliers and the rectal fascia [10].

Nerves cannot always be identified intraoperatively, which is why technology has been developed to help the surgeon. In 2004, an article was published in which a nerve stimulation device (CaverMap) was used to help identify intraoperative and confirm the preservation of these nerve structures. Thus, sexually active patients who underwent total excision of mesorectum were enrolled. During the dissection, the surgeon attempted to locate the hypogastric nerves in the corpus cavernous. CaverMap has been used to confirm their location and to facilitate their identification in uncertain cases. Upon completion of the proctectomy, the nerves were restimulated to confirm their preservation. 29 patients were included with an average age of 58 years old. In 26 cases, nerve identification was attempted, but only 73% (19) of cases could be achieved. In 6 out of 7, CaverMap device successfully identified. At the end of the proctectomy, the device was used for stimulation to confirm nerve preservation.

Although this device has been used successfully in the cases presented, an analysis is needed for larger batches of patients [11].

A meta-analysis published in 2011 by Moszkowicz an colleagues tried to draw attention to the key moments during dissection when these nerve structures may be injured. During the inferior mesenteric artery ligation and retro rectal dissection, the superior hypogastric plexus and/or the hypogastric nerves may be damaged. Antero-lateral dissection and division of the Denonvilliers fascia can injure the inferior hypogastric plexus and the efferent pathways. Perineal dissection can damage the pudendal nerves. The authors conclude that in most of the cases pelvic nerves can be preserved during the total excision of the mesorectum, but to obtain oncological resection, dissection must be as close as possible to the nerve structures [12].

With the introduction of neoadjuvant chemo-radiotherapy, obtaining a nerve preservation resection has become technically more difficult due to the local postradiotherapy treatment and more difficult dissection. Again, the technology helps the surgeon to achieve optimal results with minimal mortality and morbidity.

Laparoscopy an be used in the oncological surgery of the rectum, with a radical resection, as well as the preservation of pelvic plexus and nerves. Preservation of the pre-aortic plexus by ligation of the inferior mesenteric artery at 1-2 cm from aortic emergence with meticulous dissection of the mesosigmoid and mesorectum transition zone, identification of holy-plane and hypogastric nerves during the posterior and lateral dissection with nerve preservation up to the pelvic diaphragm with the identification of the lateral ligaments and inferior hypogastric plexus (10 and 2). The ligaments were split at the level of endopelvic fascia of the mesorectum to avoid injury of the inferior hypogastric plexus; lateral dissection at the edge of Denonvillier fascia, where the inferior hypogastric plexus is adjacent to the neurovascular bundles. Liang et al. included only patients with complete preservation of nerve structures and preoperative sphincter and sexual function. Sexual functions was analyzed in terms of potency and ejaculation in men, and from the point of view of vaginal lubrication, dyspareunia, sexual arousal and climax in the case of women. Patients were interviewed 6 months postoperatively (when reintegration of intestinal transit was performed) and at the end of convalescence. There were 98 patients, stage II – 44 and stage III – 54 (50 males and 48 females). 89 of these patients were operated laparoscopically with nerve preservation. The mean time for maintain urinary catheter was 7 days, with good urinary function in 71.6% of cases, satisfactorily in 23% and weak in 5.4%. Of the 17 patents with poor urinary function, in 8 of these patients, these conditions were transient. 32 males and 28 women with preoperative sexual activity completed the sexual function questionnaire. Ejaculation was good at 56.3%, satisfactorily in 18.7% and unsatisfactorily (retrograde ejaculation or impossibility of ejaculation) in 25% of patients. The potency was good in 62.5%, satisfactorily in 53.6% and unsatisfactorily in 21.9% of patients. For women, sexual function was good in 53.6%, satisfactorily in 14.3% and unsatisfactorily in 32.1%. The absence of vaginal lubrication was found in 46.6%, 39.3% dyspareunia, 28.6% lack of sexual arousal and in 32.1% anorgasmia [13]the aim of which is to determine if a laparoscopic approach can be

used in pelvic autonomic nerve-preserving surgery for patients with lower rectal cancer following chemoradiation therapy. Methods: Patients with T3 lower rectal cancer treated by preoperative chemoradiation were recruited and subjected to laparoscopic pelvic autonomic nerve-preserving surgery with total mesorectal excision and a sphincter-saving procedure. This study was performed with the approval of the ethics committee of National Taiwan University Hospital. Because the quality of a surgical trial is highly dependent on the skill of the surgeon with respect to the technique under study, it is imperative that a surgical trial only be implemented after the surgical technique has been judged to be mature. Before the start of this clinical trial, we gained a sound knowledge of surgical anatomy through conventional open surgery for rectal cancer and mastered the related laparoscopic skills from other sound and proven laparoscopic approaches, including right hemicolectomy, left hemicolectomy, among others. We determined that the learning curve for this surgical technique necessitated that colorectal surgeons carry out at least 20 such procedures. At this point we conducted this clinical trial. The details of the surgical procedures have been shown in the attached video. Briefly, the dissection commences at the pelvic promontory with exposure and preservation of the superior hypogastric plexus. The pre-aortic plexus and inferior mesenteric plexus are preserved by sparing the pre-aortic connective tissue and leaving a 1- to 2-cm-long stump of the inferior mesenteric artery in situ. Subsequently, the \"holy plane\" at the transition of the mesosigmoid to the mesorectum is meticulously dissected to progressively displace the hypogastric nerves dorsally and laterally and, therefore, preserving them. Following adequate dorsal and lateral dissection down to the floor of the pelvis, the so-called lateral ligament is reached at which the mesorectum appears to be adherent, anteriorly and laterally, to the inferior hypogastric plexus (at roughly 10:00-2:00 O'clock or within an angle of 60degrees about symphysis on both sides.

In 2013 Runkel and colleagues developed NOME – a nerve-oriented mesorectal excision consisting of identifying anatomical features for nerve preservation in laparoscopic rectal resection. They consider the pelvic nerves to be the benchmarks for standard dissection between the planes of the pelvic fasciae. The key points are: preparation for the splanchnic nerves at the median region of postero-lateral wall, hypogastric nerves superiorly at the lateral wall and urogenital bendlets antero-inferiorly at the lateral wall. Dissection of lateral ligaments is performed last. NOME was applied by the authors in 274 cases with partial or total excision of mesorectum (20.4% and 79.6% respectively). 42 men completed a sexual activity questionnaire. The conversion rate was 0.7%. The complete R0 resection was obtained in 90.1% and 95.3% respectively. The anastomosis fistula was found in 4.7% of the cases, and the mortality rate was 1.8%. Out of the 22 sexually active males interviewed, 81% of them maintained satisfactorily sexual activity in the postoperative period. In conclusion, NOME resections are an alternative treatment for rectal neoplasms, achieving morbidity and mortality compared to gold-standard technique [14]the hypogastric nerves at the upper sidewall, and the urogenital nerve branches (Walsh.

Robot surgery attempts to overcome certain limits of conventional laparoscopic sur-

gery. Andolfi et al. published a review of literature in 2018, where results from robotic surgery can be compared to laparoscopy from the point of view of oncology and short-term morbidity and mortality. The shortcomings of this type of intervention are high costs and operating time, but with a shorter learning curve. It has greater potential for rectal surgery due to the low conversion rate. Some studies also show a lower rate of anastomosis fistula, positive resection margins and better preservation of autonomous function [15].

Another study, published by Askild et al. in 2018, compares robotic surgery with laparoscopy from the point of view of postoperative period, short-term results and compliance with the Enhanced Recovery After Surgery (ERAS) protocol. The cohort included 224 patients who underwent a rectal resection for adenocarcinoma. 47 of the patients are part of the laparoscopy group, and 72 patients are in the robotic surgery group. For the robotic surgery the duration of hospitalization was lower (3 days vs. 7 days), had a lower conversion rate (11.1% vs. 34%), a lower postoperative complication rate (24% vs. 49%), but a longer operative time (5.8 hours compared with 4.5 hours). Compliance with the ERAS protocol was 81.1% for the robotic group and 83.4% for the laparoscopic group [16].

The robotic system attempts to overcome the shortcomings of open surgery, such as the narrow field of vision, given the localization of the rectum in a confined space, adhesion of the mesorectal fascia and the difficult identification of autonomic nerves in such a restrictive space. The development of this technology has led to overcoming these impediments with better results in preserving the nerve structures involved in genito-urinary functions by identifying the intraoperatively superior hypogastric plexus, hypogastric nerves, inferior hypogastric plexus and neurovascular bandlets [17,18]we successfully conducted transabdominal intersphincteric resection (ISR.

Luca F. and colleagues analyzed urinary and sexual function after robotic rectal resections with complete excision of mesorectum. They included 74 patients whos underwent such surgery. Sexual and urinary function was analyzed by pre-and-postoperative questionnaires. Sexual function at 1 postoperative month was considerably diminished with erectile dysfunction and decreased sexual satisfaction in men, and for women decreased libido and sexual satisfaction. Both functions, for both sexes, improved in the later period, so at 1 year postoperative the results were comparable with the ones before the surgery. From the point of view of urinary function, the degree of incontinence at one year after the intervention was unchanged for both sexes [19]74 patients undergoing fully robotic resection for rectal cancer were prospectively included in the study. Urinary and sexual dysfunctions affecting quality of life were assessed with specific self-administered questionnaires in all patients undergoing robotic total mesorectal excision (RTME.

Surgical resections for intestinal inflammatory diseases

Colonic inflammatory diseases, Chron disease and ulcerative hemorrhage recto-colitis (UHRC) are severe diseases of the digestive tract with common clinical, pathological and epidemiological affections, that affect young adults in particular, are incurable, require lifelong treatment, and sometimes multiple surgical interventions (intestinal resections, proctocolectomy, ileostomies, colectomy, etc.). The physiopathological mechanism of these diseases is the inflammation of the intestinal mucosa that can progress to ulceration, edema and bleeding. In UHRC, inflammation begins at the rectum where it can spread to the colon from close to closer affecting the entire large intestine. Unlike Chron's disease, where inflammation can affect any region of the digestive tract, with healthy areas between two regions affected by inflammation. Inflammatory diseases are associated with multiple gastrointestinal complications: toxic megacolon, hemorrhages, perforations, strictures, fistulas and perianal abscesses (all representing acute complications requiring surgical management); chronic inflammation increases the risk of gastro-intestinal neoplasia.

The treatment of inflammatory bowel disease is made up of two therapeutic steps: obtaining remission under appropriate medical treatment and preventing the disease being reactivated. Sometimes both medical and surgical treatment is needed. Surgical treatment of these diseases is encumbered a series of complications to which is added the inferior hypogastric plexus injury with consequences on urogenital functions.

An understanding of the anatomy and physiology of normal sexual function in men and women is essential to clarify more postoperative sexual disorders. Organic sexual dysfunction after proctocolectomy is more common in males than in females. The narrow conical pelvis makes frequent rectal mobilization more traumatic than in women, and nerves can be cut or elongated, resulting in a variety of postoperative sexual disorders. In addition, the increased incidence of male sexual dysfunction can be explained by the fact that in men only nerve disruption can completely eliminate erectile function. In women, sexual function can primarily be mediated by brain sexual centers and the impulses carried by pudendal nerves. Occasionally, men may have normal erectile function, but may experience retrograde ejaculation, as a postoperative complication or rectal excision. This is neurophysiological explained by the fact that the sympathetic nerves have been injured, the most likely location for this event being the disruption of the nerves at the sacral promontorium. At this level, sympathetic nerves are exposed, which are easily damaged during mobilization of the rectum. Thus retrograde ejaculation occurs, allowing sperm to go retrograde into the bladder rather than being expressed through the outside of the penis [20].

Rectal excision is associated with a risk of autonomous nervous system damage followed by sexual dysfunction (SD). The evolution of our understanding of the anatomy and physiology of sexual function, along with continuous improvement of surgery for both benign and malignant disease, led to decrease in the incidence of SD after

rectal surgery. A knowledge of postoperative SD risk is important for both the patient and the reference point for the audit of individual colorectal practice [21]physiology and surgical aspects of this topic has been researched through the Medline database. The more recently available data are reviewed in the context of the historical evolution of surgery for benign and malignant rectal disease.

RESULTS AND CONCLUSIONS

In the best hands, permanent impotence occurs in less than 2% of patients following restorative proctocolectomy and at a similarly low rate after proctocolectomy and ileostomy. Isolated ejaculatory dysfunction is also numerically a minor problem post operation for benign disease. Patient age is the most important predictor of SD after surgery for rectal cancer. The incidence of permanent impotence remains high (>40%).

A study from 2004 [21]physiology and surgical aspects of this topic has been researched through the Medline database. The more recently available data are reviewed in the context of the historical evolution of surgery for benign and malignant rectal disease. RESULTS AND CONCLUSIONS In the best hands, permanent impotence occurs in less than 2% of patients following restorative proctocolectomy and at a similarly low rate after proctocolectomy and ileostomy. Isolated ejaculatory dysfunction is also numerically a minor problem post operation for benign disease. Patient age is the most important predictor of SD after surgery for rectal cancer. The incidence of permanent impotence remains high (>40% shows that permanent impotence occurs in less than 2% of patients following restorative proctocolectomy and at a similar low rate after proctocolectomy and ileostomy. On the other hand, the age of the patient is the most important predictor of postoperative SD. The anatomical dissection of the pelvis with the preservation of said autonomic fibers leads to a low and predictable rate of sexual morbidity. Further research is needed to determine the effects of adjuvant therapy for rectal cancer on sexual function. The rectal dissection performed inside the mesorectum, close to the rectal muscle wall, in order to minimize the damage of pelvic sexual nerves to inflammatory bowel disease, can be performed with low impotence rate. Minor degrees of erectile disfunction may be more common than those currently recognized. I could not be demonstrated that a rectal wall significantly protects the patients from impotence compared to operation in the anatomical mesorectal plane. Age seems to be the most important risk factor for postoperative impotence.[22]

An ileo-anal anastomosis with the formation of a reservoir can alter sexuality and fertility in women. The laparoscopic approach seems to reduce infertility rates in women, however, the impact of manual versus mechanical anastomosis on sexuality and fertility has never been evaluated in UHRC patients. In this preliminary study, manual or mechanical technique did not influence the results of sexuality or fertility of patients with UHRC, but there was a tendency to improve female fertility and male erectile function in the case of manual anastomoses. The intestinal transit disorders have contributed to male and female sexual dysfunction after ileo-anal anastomotic surgery [23].

14 studies have been identified; six patients with colon inflammatory diseases registered in a national database or presented in a clinical setting, while eight studies evaluated sexual function after surgery for colonic inflammatory disease. Surgery does not seem to affect sexual function in most studies, except for a prospective study that reported a significant improvement in male but not female sexual function. In conclusion, sexual function among patients with colonic inflammatory disease may be impaired, but more studies are needed to develop appropriate tools and effective management strategies. [24].

There is an important concern about the effect of proctocolectomy on sexual function in patients with colon inflammatory disease. Little is known about gender differences. A 2011 study of sixty participants (41 men and 25 women) that were evaluated at baseline and 6 months after proctocolectomy or completion of proctocolectomy. 48 ileo-anal anastomosis with reservoir (31 males and 17 females) and 18 ileostomies (10 males and 8 females) were created. Both men and women reported improvement in general and quality of life after surgery, but only men have been shown to improve sexual function. Women reported an improved sexual desire without a general improvement in sexual function. The gender postoperative difference in sexual function was not important, despite similar improvements in quality of life [24–28] quality of life, bowel habits, and urinary symptoms, and were completed before and 6 months after surgery. RESULTS Sixty-six participants (41 men and 25 women.

Conclusions

In conclusion, regardless of the surgical approach used, either open, laparoscopic or robotic, the surgeon must perform an anatomical dissection that follows the embryological anatomical plans, preserving pelvic autonomous nerve structures to preserve the urinary, sphincter and sexual functions. To maximize the postoperative quality of our patients lives, we must respect both oncological principles and pelvic anatomical structures, a through dissection offering similar results in the rate of local recurrence and overall survival.

CONFLICT OF INTERESTS

The author declare that there is no conflict of interest

References:

1. Constantinescu N, Negoi I. Anatomia chirurgicală a rectului. In: Constantinescu N, editor. Anat. Chir. a pelvisului, 2018.
2. Beuran M, Negoi I. Rectum. Surg. Anat. Abdomen, Editura Academiei Române; 2018.
3. Heald R. Rectal Cancer in the 21st Century-radical Operations: anterior Resection and Abdominoperineal excision. In: Fischer J, editor. Mastery Surg., Lippincott Williams & Wilkins; 2007, p. 1542–55.
4. Havenga K, Enker WE. Autonomic nerve preserving total mesorectal excision. Surg Clin North Am 2002;82:1009–18.
5. D. Ion, R.V. Stoian, D.N. Păduraru, A. Bolocan MBÆ. Certitudini æi controverse privind conservarea elementelor nervoase în tehnica de excizie totală a mezorectului (ETM) n.d.
6. Prete F. [Neurovascular implications in total mesorectal excisions. A prospective study of sexual function after surgery for rectal cancer]. G Chir n.d.;17:393–8.
7. Pocard M, Zinzindohoue F, Haab F, Caplin S, Parc R, Tiret E. A prospective study of sexual and urinary function before and after total mesorectal excision with autonomic nerve preservation for rectal cancer. Surgery 2002;131:368–72.

8. Maeda K, Maruta M, Utsumi T, Hosoda Y, Horibe Y. Does perifascial rectal excision (i.e. TME) when combined with the autonomic nerve-sparing technique interfere with operative radicality? Colorectal Dis 2002;4:233–9.
9. Tsunoda A, Shibusawa M, Tanizaki H, Kusano M. Hypogastric nerve preservation does not increase local recurrence after surgical treatment of rectal carcinoma. Hepatogastroenterology n.d.;51:1354–7.
10. Ma G, Wang Y, Liang X. [Anatomical basis and main points of pelvic autonomic nerve preserving in proctectomy]. Zhonghua Wei Chang Wai Ke Za Zhi 2014;17:570–3.
11. da Silva GM, Zmora O, Börjesson L, Mizhari N, Daniel N, Khandwala F, et al. The Efficacy of a Nerve Stimulator (Cavermap®) to Enhance Autonomic Nerve Identification and Confirm Nerve Preservation During Total Mesorectal Excision. Dis Colon Rectum 2004;47:2032–8. doi:10.1007/s10350-004-0718-5.
12. Moszkowicz D, Alsaid B, Bessede T, Penna C, Nordlinger B, Benoît G, et al. Where does pelvic nerve injury occur during rectal surgery for cancer? Color Dis 2011;13:1326–34. doi:10.1111/j.1463-1318.2010.02384.x.
13. Liang JT, Lai HS, Lee PH. Laparoscopic pelvic autonomic nerve-preserving surgery for patients with lower rectal cancer after chemoradiation therapy. Ann Surg Oncol 2007;14:1285–7. doi:10.1245/s10434-006-9052-6.
14. Runkel N, Reiser H. Nerve-oriented mesorectal excision (NOME): autonomic nerves as landmarks for laparoscopic rectal resection. Int J Colorectal Dis 2013;28:1367–75. doi:10.1007/s00384-013-1705-x.
15. [15] Andolfi C, Umanskiy K. Appraisal and Current Considerations of Robotics in Colon and Rectal Surgery. J Laparoendosc Adv Surg Tech 2018:lap.2018.0571. doi:10.1089/lap.2018.0571.
16. Asklid D, Gerjy R, Hjern F, Pekkari K, Gustafsson UO. Robotic *vs* laparoscopic rectal tumour surgery: a cohort study. Color Dis 2018;21:codi.14475. doi:10.1111/codi.14475.
17. Park SY, Choi G-S, Park JS, Kim HJ, Choi W-H, Ryuk JP. Robotic-assisted Transabdominal Intersphincteric Resection. Surg Laparosc Endosc Percutan Tech 2013;23:e5–10. doi:10.1097/SLE.0b013e318275b27a.
18. Kim NK, Kim YW, Cho MS. Total mesorectal excision for rectal cancer with emphasis on pelvic autonomic nerve preservation: Expert technical tips for robotic surgery. Surg Oncol 2015;24:172–80. doi:10.1016/j.suronc.2015.06.012.
19. Luca F, Valvo M, Ghezzi TL, Zuccaro M, Cenciarelli S, Trovato C, et al. Impact of Robotic Surgery on Sexual and Urinary Functions After Fully Robotic Nerve-Sparing Total Mesorectal Excision for Rectal Cancer. Ann Surg 2013;257:672–8. doi:10.1097/SLA.0b013e318269d03b.
20. Bauer JJ, Gelernt IM, Salky B, Kreel I. Sexual dysfunction following proctocolectomy for benign disease of the colon and rectum. Ann Surg 1983;197:363–7.
21. Keating JP. Sexual function after rectal excision. ANZ J Surg 2004;74:248–59. doi:10.1111/j.1445-2197.2004.02954.x.
22. Lindsey I, George BD, Kettlewell MG, Mortensen NJ. Impotence after mesorectal and close rectal dissection for inflammatory bowel disease. Dis Colon Rectum 2001;44:831–5.
23. Harnoy Y, Desfourneaux V, Bouguen G, Rayar M, Meunier B, Siproudhis L, et al. Sexuality and fertility outcomes after hand sewn versus stapled ileal pouch anal anastomosis for ulcerative colitis. J Surg Res 2016;200:66–72. doi:10.1016/j.jss.2015.06.054.
24. Mantzouranis G, Fafliora E, Glanztounis G, Christodoulou DK, Katsanos KH. Inflammatory Bowel Disease and Sexual Function in Male and Female Patients: An Update on Evidence in the Past Ten Years. J Crohn's Colitis 2015;9:1160–8. doi:10.1093/ecco-jcc/jjv140.
25. Wang JY, Hart SL, Wilkowski KSY, Lee JW, Delmotte EC, del Rosario KM, et al. Gender-specific differences in pelvic organ function after proctectomy for inflammatory bowel disease. Dis Colon Rectum 2011;54:66–76. doi:10.1007/DCR.0b013e3181fd48d2.
26. [26] Memon MA, Yunus RM, Memon B, Awaiz A, Khan S. A Meta-Analysis and Systematic Review of Perioperative Outcomes of Laparoscopic-assisted Rectal Resection (LARR) Versus Open Rectal Resection (ORR) for Carcinoma. Surg Laparosc Endosc Percutan Tech 2018;28:337–48. doi:10.1097/SLE.0000000000000589.
27. Lin Z, Jiang Z-L, Chen D-Y, Chen M-F, Chen L-H, Zhou P, et al. Short- and long-term outcomes of laparoscopic versus open surgery for rectal cancer. Medicine (Baltimore) 2018;97:e13704. doi:10.1097/MD.0000000000013704.
28. Truong A, Lopez N, Fleshner P, Zaghiyan K. Preservation of Pathologic Outcomes in Robotic versus Open Resection for Rectal Cancer: Can the Robot Fill the Minimally Invasive Gap? Am Surg 2018;84:1876–81.

Points of View

Received: 12.02.2019
Accepted: 6.03.2019

THE „H" HYPEREROTICISM AREA ESSENTIAL FOR FEMALE EXCITABILITY – POINTS OF VIEW

V. NIȚESCU
Medical Obstetrics-Gynaecology and Sexology Centre

Known for a long time as a woman's erogenous area, Ernst Gräfenberg emits the hypothesis of a "spot" that would cause a woman's pleasure state, which he called "G". It has not been explained how and why, there is a hyperexcitability at the touch of the area, respectively the morpho-physiology of this place.

In 2016, we have proved that it is not a "spot", but a distinct well-defined "area" with a specific and well-defined structure in relation to the other erogenous areas [1,2]; we have also explained that the Area is not hypothetical, that the intensity of its orgasm is not different from the vaginal, anal or clitoridian orgasm, and ejaculation is normal, but not abundant [1,2,8,9,10,11].

Regarding the existence of the "G-spot" [4,5,6,7,8], in 2009, authors from King's College London, as well as other authors, suggested that the "G-spot" was subjective, and they explained this by the fact that in 2 twins [5,8], only one reported the so-called "G-spot", and the other did not.

In a study on 800 women aged 16-45 we found that:

On the anterior-inferior retropubic vaginal wall there is a surface with a higher erectile sensitivity than the rest of the vagina, with a

*mailing address: [1]Prof. Univ. As. Dr. Nițescu Vasile,
E-mail: jcs.editorial.board@gmail.com

Fig. 1 a

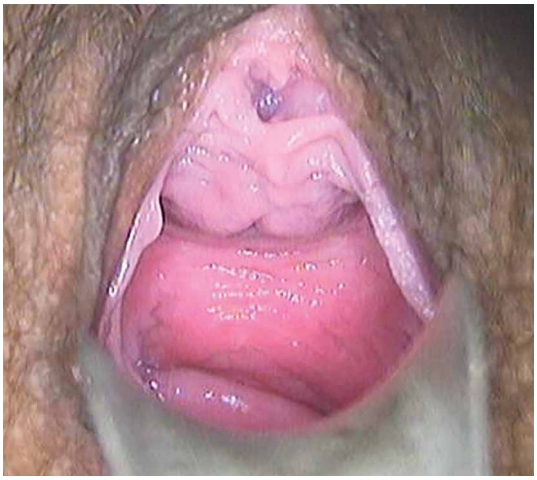

Fig. 1 b

Figure 1 a, b. The Hypereroticism Area- The H Area

differentiated macroscopic aspect (Fig.1a.b), namely a separate morphological structure that justifies this sensitivity.

The erectile area has a unique and precise trapezoidal shape (Fig.2).

Figure 2 The trapezoidal shape of the H Area

The H Area is not present in absolutely all women, just like orgasm. This does not mean that, according to some authors, the area would not exist.

The intensity of the excitability of the H Area is determined by multiple factors such as the biological potential, the partner, or the state of the woman at that moment since there are women who, for example, do not have orgasm after the self-masturbation or the hetero-masturbation of the area, respectively a fertilizing coitus proving once again the diverse human body structure.

The difference is also between the erectile organs, such as the erectile organs of the vulva through their structure.

The sensitivity of the erectile structure of the clitoris may not be the same as the sensitivity given by the vestibular bulbs, imperfectly developed organs, located on the lateral sides of the vaginal opening, at the basis of the labia minora.

Morphophysiological features that define the Hypereroticism Area ("the H Area")

The lower third of the vagina (the H Area), respectively the two upper thirds have different embryological origins.

The two upper thirds of the vagina come from the urogenital sinus, and the lower third from the genital ridge [3].

The muscular formations that make up the urethra's own sphincter and the vagina's own sphincter include the H Area, being involved in the erection, orgasm and ejaculation through the common neuro-vascular system.

Blood vessels, lymph vessels and nerves are directly linked to the vulvar sensory corpuscles, integrating directly into the highly sensitive erogenous structures.

The lower third of the vagina results from the urethrovaginal sinus from which the urinary bladder and urethra are formed, there being a direct link between the anatomical structure of the H Area and the urethra, the vulvar erectile organs and the common vascular-nervous formations.

The response to stimuli is slightly superior in the lower third of the vagina as compared to the two upper thirds, with a time span between the stimulus application and net response lower for the H Area [1,2], and the resting potential is shorter for the cells in the H Area.

The urethra, suburethral tissue and vaginal opening are surrounded by vestibular bulbs, which in the anterior and median position, above the urethra, constitute a venous plexus communicating with the corpus cavernosus of the clitoris. This is another proof of the connection between the erogenous area and organs with the H Area. The corpus cavernosus of the clitoris and the vestibular bulbs have cavernous tissue in their structure, which is filled with blood during the erection, through the dilated helicine arteries which are strained due to the albuginea, obstructing the veins, namely the blood drainage system.

The vascularization of the erectile system in the area directly concerns the urethral bourrelet made of erectile tissue, located in the urethrovaginal area, and therefore affecting the H Area.

In this context, the direct connection between the erectile tissue of the clitoris, the vestibular bulbs, the urethral tissue, the urethrovaginal tissue, and the H Area vascular plexus causes through the stimulation of the receptors in the H Area an erectile effect, turgescent on a large surface, preparing the genital organs for copulation, ejaculation and orgasm.

The anastomoses between the corpus cavernosus of the clitoris with the corpus cavernosum of the urethra are also explained by the venous blood leakage, mainly directly into the circumflex veins [1,2,3].

The erection is therefore a complex vascular-nervous process in which the relaxation of the cavernous spaces, the "erotic state", is made in response to the excitation of the local and central nervous receptors, preparing the act of mating.

The blood flow to the venous plexus of the anterior wall of the vagina causes a normal erectile state, which, however, in the H Area is supplemented by the hyperaemia of the local spongy tissue, which increases the erecti-

on and sensitivity of the receptors, increasing the intensity of the excitation, another proof of the existence of the Hypereroticism Area.

The H Area is innervated by branches of the dorsal nerve of the clitoris, a line from the pudendal nerve. Apart from the clitoris, the nerve threads innervate the subclitoridian part, the vaginal introitus and the H Area, along with the labial, vaginal, vulvar lines at the surface and in depth, making another direct connection with the other genital organs.

I recall that the nerve threads of the dorsal nerve of the clitoris make in the "gland" a nervous plexus with very high erotic sensitivity, which gives the special excitatory feeling (hyperexcitation) of the clitoris, the most powerful erogenous organ in the woman.

The connection through the nerve threads of the H Area with the clitoris, vagina and vulva is a functional erotic complex required for copulation.

Through the dorsal nerve of the clitoris that innervate the H Area, the urethra, the vestibular bulbs and the upper third of the labia minora a nervous network is created, which upon reaching one of them determines the sensitivity of the whole area. Thus, the surgical section of some lines secondary to local pathology will not completely eradicate the state of local eroticism. The sensitivity differentiation of certain spots is determined by the number of receptors, or the lowering of their excitation threshold, of the number of nerve threads leading the information.

The sensation of urinating when palpating the H Area (present in 68% of cases in our statistics) proves the direct connection of the lower third of the vagina with the urethra and the bladder.

Conclusions

The H Area is part of the group that constitutes the woman's erogenous areas and organs.

The direct connection with the clitoris, an organ with very high erotic sensitivity, especially through the nerve threads, gives a good erogenous value to the H Area.

Certain structural, anatomical or pathological particularities that alter the erotic sensitivity of the erogenous area or organs cannot be generalised.

CONFLICT OF INTERESTS

The author declare that there is no conflict of interest

References

1. Nițescu Vasile, Treaty Of Clinical Sexology, The Publishing House Of The Romanian Academy; "The Vaginal Area Of Hypereroticism (The H Area)" P.51-58; ISBN 978-973-27-2574-0, 2018.
2. Nițescu Vasile, Tratat de Sexologie Clinică, P.56-61, Editura Didactică și Pedagogică București ISBN 978-973-30-3806-1, 2015.
3. Bareliuc Lucia, Neagu Natalia - Embriologie umană normală și patologică, Ed.Medicală București, p 293-306, 1987.
4. Balon Richard, Taylor Robert - Segraves Clinical Manual Of Sexual Disorders, American Psychiatric Publishing-P.258, ISBN-1585629057,(2009).
5. Jerrord S. Greenberg, Clint E Bruess, Sara B. Oswalt- Exploring The Dimensions Of Human Sexuality- Jones Bartlett Publishers Pp.102- 104, ISBN -1449648517,(2014).
6. Hines T- "The G-Spot; A Modern Gynecologic Myth". Am J.Obstet-Gynecol;185(2) 359-362 PMID.11518892 (2001).
7. Kilchevsky A.,Vorodi Y., Lowenstein L., Gruenwald J.,- " Is The Female G-Spot Truly A Distinct Anatomic Entity?" ;The Journal Of Sexual Medicine 9(3),719-26,(2012).
8. See page 98 for the 2009 King's College London's findings on the G-spot and page 145 for ultrasound/ physiological material with regard to the G-spot. Ashton Action (2012) Issues in sexuality and sexual behavior. Research: 2011 edition. scholarly edition, ISBN 1464966877.
9. "BBC News- The G –Spot doesn't apper to exist" Say Researchers, 2010.
10. Roberts Yvonne- The Real G-Spot Myth", Guardian.Co.Uk. The Guardian London, 2010.
11. Lais Rogers: "What An Anti –Climax : G-Spot Is A Myth- Times Online. The Times. London ,2010.

Correspondence

Q: Why is it that women can have sexual intercourse even in the absence of excitation leading to it, while men cannot copulate without an erection, i.e. they cannot have a sperm release or orgasm? Which are the common excitation factors of the two parteners?

A: Normal intercourse is the result of the excitation of the 2 individuals involved. Determining the erotic sensation, i.e. the libido, may be triggered also by seeing someone in a group, the touching of whom causes the erectile sensation in the genitalia and the desire to have sexual intercourse.

The state of sexual excitation of a person, be that a woman or a man, is the result of both exogenous, and endogenous factors.

The endogenous factors include the following:

-Pheromones, which cause the changes in a person's sexual conduct, i.e. the attraction of the partner.

In mammals, pheromones apparently result from the alteration of the fatty acids in the vagina by the action of the estrogen, which changes the vaginal PH. Lower quantities of pheromones also occur in the pre-ovulation period of the menstrual cycle (1,2).

-Psychological factors, such as the remembrance of highly erotic sexual images, the intimate, sensual dance, as part of which being close to your partner causes an erogenous impulse; the lascivious movements of a woman and the touching of the more erotically charged parts (the thighs, the vulva, the penis), the viewing of sexual images of any form, particularly following a period of abstinence of the person in question, may result in an erectile tonus. Sexual attractiveness and bilateral receptiveness, the directing and activation of sexual motivation, i.e. the role neurohormones and cybernins in the brain play in this deterministic equation is still not completely elucidated.

- Low temperatures increase the secretion of TSH, thus stimulating prolactin secretion, which reduces dopamine, i.e. the desire to have intercourse.

-High temperatures stimulate erection, and have a positive effect on gonads.

- The state of excitation in individuals may be triggered by olfactive, auditory and visual analysers, as well as by the tactile receptors situated in the skin follicles and the cutaneous ridges with non-myelinic nervous fibres (the Merkel cells). Sexual excitation in men and women is transmitted by the tactile stimulation of tactile receptors in the erogenous zones, which causes the specific erotic state in the brain (1,3).

From receptors, impulses reach the erectile centre in the bone marrow of S2-S4, and

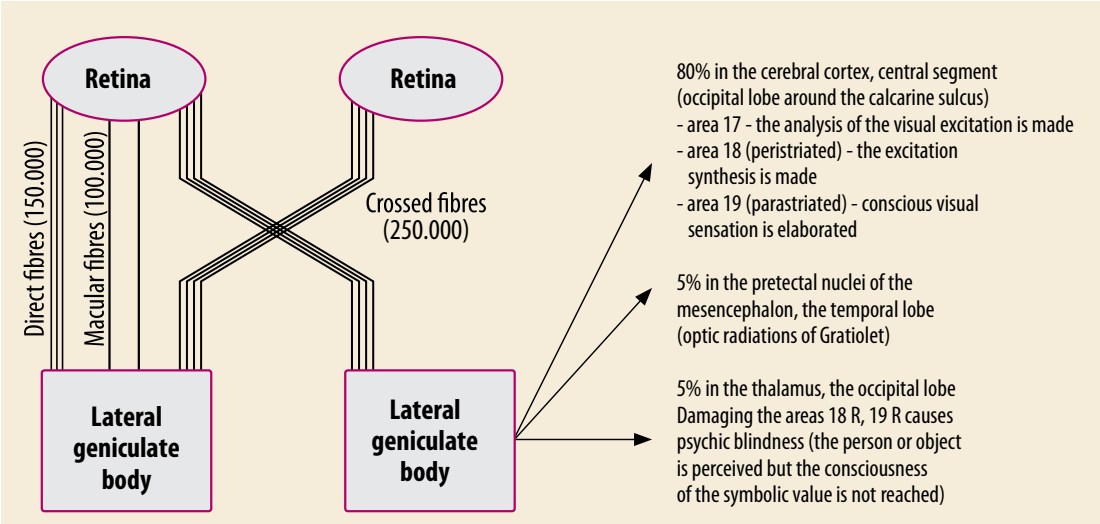

Figure 1 . The optic nerve (image from Treaty of Clinical Sexology)

from here, through the medullary ascending paths, reaching the postcentral gyrus in the parietal lobe. From the brain level, modifications in the genitalia occur through descending paths, such as the elongation and distension of the vagina, the congestion of the labia and the other erectile zones, the clitoris and vestibular bulbs, the H Zone, i.e. the swelling of the nipple and the erection of the penis.

In addition to the CNS, tactile receptors also engage the cardiovascular and respiratory apparatuses, and have a direct effect on sexual intercourse.

-Visual analysers – shapes conveying the sense of sensuality of men and women are perceived by the most important and most sophisticated analyser, which consists of over 500,000 fibres (Fig.1). It plays a major role in the occurrence and enhancing of the erogenous sensation, it being the trigger. It is well-known that the viewing of overdeveloped genitalia causes the young man/woman to become aroused, not being aware that a really big penis will result in painful copulation for the woman, while very wide vaginas will reduce the man's pleasure during the intercourse. In this case, however, a man's hetero-masturbation causes the woman to become extremely aroused and have multiple orgasms. Humans receive 1.5% of data by touching, 3.5% by smelling, 11% by hearing, and 83% by seeing.

Sight provides humans with up to 90% of the total volume of data in the environment, and complex visual data are interpreted by one tenth of the cerebral cortex. The retina is an outgrowth of the brain, and light receptors are located on the retina. The image enters the pupil, goes past the transparent media of the eye, where sensitive cells (rods and cones) turn the light energy into a nervous influx, which is the electrochemical information in the brain. Data collected by a single cell of the eye are sent through the retinal-cerebral

fibres of the optic nerve to the cortex, and the image of the seen person is received and sent to the brain by this analyser.

The connection of the retina to the diencephalon (Hypothalamus), i.e. the Parasympathetic Vegetative Nervous System, explains the hyperexcitability of people living in warm geographic areas, including as far as their sexual behaviour is concerned.

II- I : Why is it that in the case of humans, over 90% of women carry an only child in their pregnancy, and only approximately 10 % of pregnancies are of multiple products of conception?

R: Only one spermatozoon penetrates the oocyte; following the penetration of the first spermatozoon, an influx of Calcium ions is triggered in the "pellucid zone" which release cortical granules in the perivitelline area, which prevents other spermatozoa from penetrating it (1).

References

1. Nitescu V.:Treaty of clinical sexology, The Publishing House of The Romanian Academy, 2018
2. Wilson J.D.: Gonodal Hormones and Sexual Behavior, in Clinical Neuroendocrinology, Besser G.M., Martini L. (editors) Academic Press London, 1982.
3. Patestas MA, Gartner LP,: A Textbook of Neuroanatomy, New Age International Publishers. Blackwell Publishing, Main Street, Malden, SUA, 2008.

BTL EMSELLA®

SAY **NO** TO **INCONTINENCE**

WHO STANDS BEHIND BTL EMSELLA?

Founded in 1993, BTL has grown to become one of the world's major manufacturers of medical and aesthetic equipment. With over 1,500 employees located in more than 53 countries, BTL has revolutionized the way, offering the most advanced non-invasive solutions for body shaping, skin tightening, cellulite & other medical aesthetic treatments.

HOW DOES BTL EMSELLA WORK?

BTL EMSELLA uses electromagnetic energy to cause deep pelvic floor muscle stimulation without getting undressed! A single BTL EMSELLA session brings thousands of Kegel-like contractions which help you train your muscles without any effort. Scientific research shows that 95% of treated patients have reported significant improvement in their quality of life.**

BTL EMSELLA utilizes HIFEM to cause deep pelvic floor muscles stimulation and restoration of the neuromuscular control.
Pelvic floor muscles support the pelvic floor organs, control the continence and play a crucial role in adequate genital arousal and attainment of orgasm.

Their weakness or deconditioning provide insufficient activity necessary for vaginal friction or blood flow, and therefore inhibit orgasmic potential.
HIFEM therapy key effectiveness is based on focused electromagnetic energy, in-depth penetration, and stimulation of the entire pelvic floor area.

Key effectiveness is based on focused electromagnetic energy, in-depth penetration and stimulation of the entire pelvic floor area.
A single BTL EMSELLA session brings thousands of supramaximal pelvic floor muscle contractions, which are extremely important in muscle re-education of incontinent patients, women after childbirth and those with decreased intimate satisfaction.

BEFORE

- Poor pelvic floor muscle awareness and ability to contract muscles
- Uncontrolled urine leakage
- Loss of neuromuscular control
- Weak pelvic floor muscles

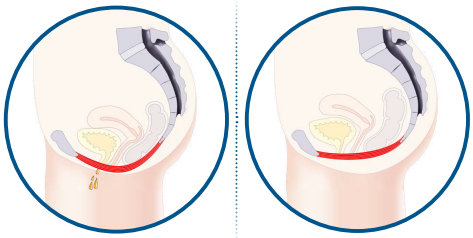

AFTER

- Improved awareness and ability to contract pelvic floor muscles
- Regained bladder control
- Restoration of neuromuscular control
- Deep pelvic floor muscle stimulation and strengthening

** HIFEM Technology Can Improve Quality of Life of Incontinent Patients Berenholz J., MD, Sims T., MD, Botros G., MD

TARGET RIGHT CANDIDATES!

1. AFTER CHILDBIRTH CONDITION

Almost 80% of women after vaginal delivery were unable to properly contract their pelvic floor muscles 1 year after having a baby!* Offer BTL EMSELLA to all your patients after childbirth to prevent incontinence, prolapse or intimate discomfort.

2. WOMEN WITH DECREASED INTIMATE SATISFACTION

Up to 63% is the worldwide prevalence of female sexual dysfunction.* Body aging, hormonal changes, multiple childbirths change the quality of all pelvic floor tissues and muscles which play a crucial role during intercourse.

3. INCONTINENCE

Did you know that 200 million people suffer from some type of incontinence?* Who are they?
- Young women typically after childbirth
- Women in pre- and post-menopausal age
- Men after prostatectomy

4. POST-SURGICAL CONDITION

Approximately 600 000 hysterectomies are performed annually in the United States. Every surgical intervention also affects pelvic floor muscles. Offer to your patients post-surgical care to maintain the strength of pelvic floor muscles.

5. ORGAN PROLAPSE

Pelvic floor muscles support the pelvic floor organs. Their weakness negatively contributes to loss of vaginal or uterine support. Did you know that these symptoms are seen in up to 76% of women presenting for routine gynecology care?* Who are they?
- Women in pre- and post-menopausal age
- Women after multiple vaginal childbirths

6. WOMEN UNDERGOING INTRAVAGINAL PROCEDURES

Do you have existing patients that are undergoing intravaginal RF or laser treatment? Did you know that these technologies affect mainly collagen, elastin, blood flow but do not address pelvic floor muscles? Offer an ultimate combo with BTL EMSELLA to boost the clinical outcome!

BENEFITS OF BTL EMSELLA

- A non-invasive procedure with no recovery time.
- Remain fully clothed during treatment.
- Restores bladder and pelvic muscle control without time-consuming exercises.
- A comfortable procedure that lets you relax during the 28-minute treatment.
- You may observe improvement after a single session. Results will typically continue improving over the next few weeks.
- Results after about six sessions, scheduled twice a week.
- Patients have reported a significant pad reduction.**

**HIFEM Technology Can Improve Quality of Life of Incontinent Patients, Berenholz J., MD, Sims T., MD, Botros G., MD, Individual results may vary

About Treaty of Clinical Sexology

This treaty is the revised and enlarged edition of the book entitled "Clinical Sexology". The publishing of the first edition of this book started from the idea of a systematisation of the basic concepts of sexology, a specialized manual allowing the easy understanding of the concepts that we have placed in the framework of the simple laws of nature.

Shortly after the publication of the first edition of the "Clinical Sexology", I was suggested that I have this book translated into several languages on multiple occasions.

I am now convinced that there is a growing interest in reading this book. Moreover, the interest in the concepts of sexology also existed about 30 years ago, when my first sexology book entitled "Adolescence" sold 250,000 copies.

In this edition I also tried to make a betterclassification of the male and the female sexual dysfunctions, diagnosis and treatment thereof, the specific tests for each abnormality reported, their etiopathogenesis and others. It seemed natural to me that closer attention should be paid to patient-specific investigations as part of the clinical expression of sexual dysfunctions, and that a distinction be made between the genital and the extra-genital causes, since a simple clinical examination was obviously unable to detect the lesional etiopathogenetic substrate.



Also, according to the data presented, treatment is no longer limited to the prescription of a tablet, but it is complex, thereby providing a proper solution to sexual dysfunctions.

I hope that reading this book will make it easier for you to identify the cause of sexual pathological manifestations and remove randomly carried out treatment.

The Author

Bucharest 2018

RSCSHP

The Romanian Society of Clinical Sexology and Human Procreation invites you to participate at the Session of scientific communication of May 10th at the Library of the Romanian Academy.

The deadline for submiting your paper's title and abstract is April 20, 2019.

The most valuable papers will be published as articles in the Journal of Clinical Sexology.

For details visit

www.journalofclinicalsexology.com/category/news

or

societatearomanadesexologieclinica.ro/category/evenimente-medicale

Prof. As. Dr. Vasile Niţescu

valnitescu@yahoo.com, srscpu@gmail.com

(+4) 0723.151.804

Partners:

MGP MAGIC PRINT

BTL

REGINA MARIA

Journal of Clinical Sexology

Editor– in Chief: Vasile Nițescu,

President of the Romanian Society of Clinical Sexology and Human Procreation,

Phone +(40) 723 151804,

e-mail: jcs.editorial.board@gmail.com

Journal of Clinical Sexology appears four times a year and publishes original works of general and clinical, normal and pathological sexology, case presentation, editorials, views, reviews, special articles, comments, imaging. All papers are subject to scientific committee review.

CONTACT

www.societatearomanadesexologieclinica.ro , E-mail: srscpu@gmail.com

www.journalofclinicalsexology.com, E-mail: jcs.editorial.board@gmail.com

CLAIMS:

The printed edition of the Journal is avalaible only to the members of the RSCSHP Society.